

# ASE/SCA Guidelines for Performing a Comprehensive Intraoperative Multiplane Transesophageal Echocardiography Examination: Recommendations of the American Society of Echocardiography Council for Intraoperative Echocardiography and the Society of Cardiovascular Anesthesiologists Task Force for Certification in Perioperative Transesophageal Echocardiography

Jack S. Shanewise, MD\*, Albert T. Cheung, MD†, Solomon Aronson, MD‡, William J. Stewart, MD§, Richard L. Weiss, MD¶, Jonathan B. Mark, MD#, Robert M. Savage, MD||, Pamela Sears-Rogan, MD\*\*, Joseph P. Mathew, MD††, Miguel A. Quiñones, MD‡‡, Michael K. Cahalan, MD§§, and Joseph S. Savino, MD†

\*Division of Cardiac Anesthesia and Critical Care, Emory University School of Medicine, Atlanta, Georgia; †Department of Anesthesiology, University of Pennsylvania, Philadelphia, Pennsylvania; ‡Department of Anesthesia and Critical Care, University of Chicago, Chicago, Illinois; Departments of §Cardiology and ||Cardiothoracic Anesthesiology, The Cleveland Clinic Foundation, Cleveland, Ohio; ¶Department of Cardiology, University of Pennsylvania Health System, Presbyterian Medical Center, Philadelphia, Pennsylvania; #Department of Anesthesiology, Duke University Medical Center, Veterans Affairs Medical Center, Durham, North Carolina; \*\*Department of Cardiology, Washington Hospital Center, Washington, DC; ††Department of Anesthesiology, Duke University Medical Center, Durham, North Carolina; ‡‡Section of Cardiology, Baylor College of Medicine, Houston, Texas; and §§Department of Anesthesia, University of California–San Francisco, San Francisco, California

Since the introduction of transesophageal echocardiography (TEE) to the operating room in the early 1980s (1,3,4),<sup>1</sup> its effectiveness as a clinical monitor to assist in the hemodynamic management of patients during general anesthesia and its reliability to make intraoperative diagnoses during cardiac operations has been well established (5–26). In recognition of the increasing clinical applications and use of intraoperative TEE, the American Society of Echocardiography (ASE) established the Council for Intraoperative Echocardiography in 1993 to address issues related to the use of echocardiography in the operating room. In June 1997, the Council board decided to create a set of guidelines

for performing a comprehensive TEE examination composed of a set of anatomically directed cross-sectional views. The Society of Cardiovascular Anesthesiologists Task Force for Certification in Perioperative Transesophageal Echocardiography has endorsed these guidelines and standards of nomenclature for the various anatomically directed cross-sectional views of the comprehensive TEE examination. This document, therefore, is the collective result of an effort that represents the consensus view of both anesthesiologists and cardiologists who have extensive experience in intraoperative echocardiography.

The writing group has several goals in mind in creating these guidelines. The first is to facilitate training in intraoperative TEE by providing a framework in which to develop the necessary knowledge and skills. The guidelines may also enhance quality improvement by providing a means to assess the technical quality and completeness of individual studies. More consistent acquisition and description

Accepted for publication July 29, 1999.

Address correspondence and reprint requests to Sharon Perry, CAE, American Society of Echocardiography, 4101 Lake Boone Trail, Ste. 201, Raleigh, NC 27607.

<sup>1</sup> Cahalan MK, Kremer P, Schiller NB, et al. Intraoperative monitoring with two-dimensional transesophageal echocardiography [abstract]. *Anesthesiology* 1982;57:A153.

of intraoperative echocardiographic data will facilitate communication between centers and provide a basis for multicenter investigations. In recognition of the increasing availability and advantages of digital image storage, the guidelines define a set of cross-sectional views and nomenclature that constitute a comprehensive intraoperative TEE examination that could be stored in a digital format. These guidelines will encourage the industry to develop echocardiography systems that allow the quick and easy acquisition, labeling, and storage of images in the operating room, as well as a simple mechanism for side-by-side comparison of views made at different times.

The following discussion is limited to a description of a method to perform a comprehensive intraoperative echocardiographic examination and does not address specific diagnoses, which is beyond the scope of a journal article. It describes how to examine a patient with "normal" cardiac structures to establish a baseline for later comparison. A systematic and complete approach ensures that unanticipated or clinically important findings will not be overlooked. Routinely performing a comprehensive examination also increases the ability to recognize normal structures and distinguish normal variants from pathologic states, thereby broadening experience and knowledge more rapidly. The description of the examination in the guidelines is based on multiple imaging plane (multiplane) TEE technology because it represents the current state of the art and is the type of system most commonly used. Compared with single plane or biplane imaging, multiplane TEE provides the echocardiographer with a greater ability to obtain images of cross-sections with improved anatomic orientation to the structures being examined (27-31).

The writing group recognizes that individual patient characteristics, anatomic variations, pathologic features, or time constraints imposed on performing the TEE examination may limit the ability to perform every aspect of the comprehensive examination. Whereas the beginner should seek a balance between a fastidiously complete, comprehensive examination and expedience, an experienced echocardiographer can complete the recommended examination in <10 min. The TEE examination should be recorded on videotape or stored in a digital format so that individual studies can be archived and retrieved for review when necessary. The writing group also recognizes that there may be other entirely acceptable approaches and views of an intraoperative TEE examination, provided they obtain similar information in a safe manner.

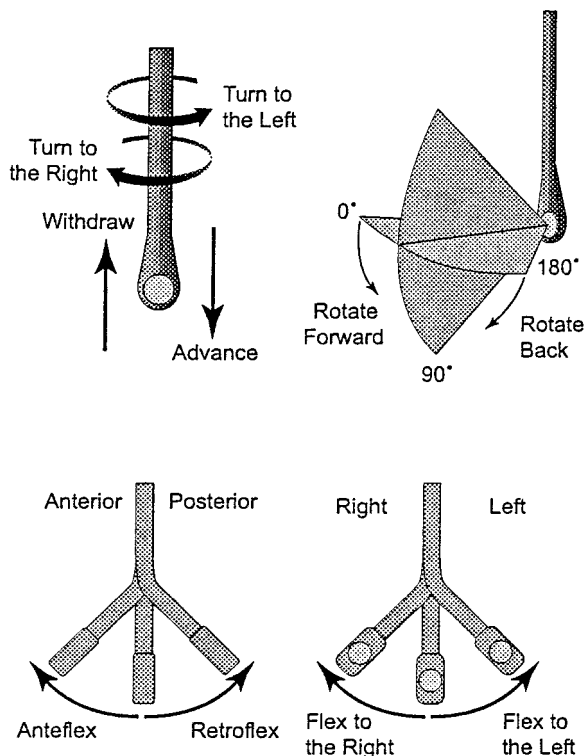
## Patient Safety

Although safe when properly conducted, in rare circumstances, TEE can cause serious and even fatal

complications (32-37). An effort should be made to detect preexisting esophageal or gastric problems before performing TEE. Contraindications to TEE include esophageal stricture, diverticulum, tumor, and recent esophageal or gastric surgery. The TEE transducer should be inspected for defects and cracks in the waterproof covering before insertion. The mouth should be examined for preexisting injuries and loose teeth. The TEE probe may be inserted into an anesthetized, tracheally intubated patient with or without the use of a laryngoscope by displacing the mandible anteriorly and inserting the probe gently in the midline. Flexing the neck will help in some cases. If blind insertion of the probe is not easy, a laryngoscope can be used to expose the glottis and permit direct passage of the probe posteriorly into the esophagus. Once in the esophagus, the transducer should never be forced through a resistance. The tip of the transducer should be allowed to return to the neutral position before advancing or withdrawing the probe, and excessive force should never be applied when moving the transducer in the esophagus or flexing the tip with the control wheels. Cleaning and decontamination of the probe should be performed after each use.

## General Principles

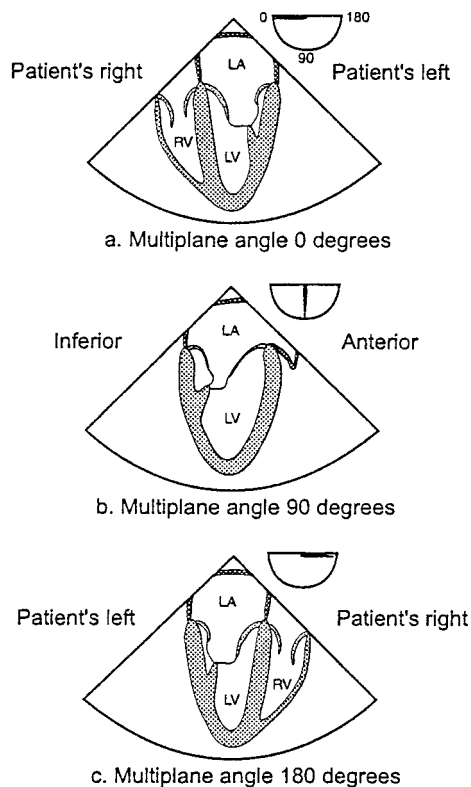
When examining the heart with TEE, the transducer is first moved into the desired location, and then the probe is manipulated to orient the imaging plane to obtain the desired cross-sectional image. This is accomplished by watching the image develop as the probe is manipulated, rather than by relying on the depth markers on the probe or the multiplane angle icon. Although the most common transducer location and multiplane angle are provided for each cross-sectional image, final adjustment of the image is based on the anatomic structures that are displayed. It is recognized that there is individual variation in the anatomic relationship of the esophagus to the heart; in some patients, the esophagus is adjacent to the lateral portion of the atrioventricular groove, whereas in others, it is directly posterior to the left atrium (LA). This relationship is taken into consideration when developing each of the desired cross-sectional views. When possible, each structure is examined in multiple imaging planes and from more than one transducer position. An echocardiograph produces a two-dimensional or tomographic imaging plane. Manipulating the probe or the transducer to move the imaging plane through the entire three-dimensional extent of a structure permits it to be examined completely.



**Figure 1.** Terminology used to describe manipulation of the probe and transducer during image acquisition.

Instrument settings and adjustments are important for optimizing image quality and the diagnostic capabilities of TEE. Many TEE probes can image with more than one transducer frequency. Increasing the imaging frequency improves resolution but decreases penetration. Structures closer to the probe, such as the aortic valve (AV), are imaged best at a higher frequency, whereas structures farther away from the probe, such as the apical regions of the left ventricle (LV), are imaged best at a lower frequency. The depth is adjusted so that the structure being examined is centered in the display, and the focus is moved to the area of interest. Overall image gain and dynamic range (compression) are adjusted so that the blood in the chambers appears nearly black and is distinct from the gray scales representing tissue. Time compensation gain adjustments are set to create uniform brightness and contrast throughout the imaging field. The color flow Doppler (CFD) gain is set to a threshold that just eliminates any background noise within the color sector. Decreasing the size and depth of the color sector increases the aliasing velocity and frame rate. Decreasing the width of the two-dimensional imaging sector also increases the frame rate.

The following terminology is used to describe manipulation of the probe and transducer during image acquisition (Figure 1). It is assumed that the patient is supine in the standard anatomic position, and the



**Figure 2.** Conventions of image display followed in the guidelines. Transducer location and the near field (vertex) of the image sector are at the top of the display screen and far field at the bottom. a, Image orientation at multiplane angle 0 degrees. b, Image orientation at multiplane angle 90 degrees. c, Image orientation at multiplane angle 180 degrees. LA = left atrium, LV = left ventricle, RV = right ventricle.

imaging plane is directed anteriorly from the esophagus through the heart. With reference to the heart, superior means toward the head, inferior toward the feet, posterior toward the spine, and anterior toward the sternum. The terms right and left denote the patient's right and left sides, except when the text refers to the image display.

Pushing the tip of the probe more distal into the esophagus or the stomach is called advancing the transducer, and pulling the tip in the opposite direction more proximally is called withdrawing. Rotating the anterior aspect of the probe clockwise within the esophagus toward the patient's right is called turning to the right, and rotating counterclockwise is called turning to the left. Flexing the tip of the probe anteriorly with the large control wheel is called anteflexing, and flexing it posteriorly is called retroflexing. Flexing the tip of the probe to the patient's right with the small control wheel is called flexing to the right, and flexing it to the patient's left is called flexing to the left. Finally, axial rotation of the multiplane angle from 0 degrees toward 180 degrees is called rotating forward, and rotating in the opposite direction toward 0 degrees is called rotating back.

**Table 1.** Recommended TEE Cross Sections

Window (depth from incisors)	Cross section (panel in Figure 3)	Multipane angle range	Structures imaged
Upper esophageal (20–25 cm)	Aortic arch long axis (s)	0°	aortic arch, left brachio v
	Aortic arch short axis (t)	90°	aortic arch, PA, PV, left brachio v
Mid esophageal (30–40 cm)	Four-chamber (a)	0°–20°	LV, LA, RV, RA, MV, TV, IAS
	Mitral commissural (g)	60°–70°	MV, LV, LA
	Two-chamber (b)	80°–100°	LV, LA, LAA, MV, CS
	Long axis (c)	120°–160°	LV, LA, AV, LVOT, MV, asc aorta
	RV inflow-outflow (m)	60°–90°	RV, RA, TV, RVOT, PV, PA
	AV short axis (h)	30°–60°	AV, IAS, coronary ostia, LVOT, PV
	AV long axis (i)	120°–160°	AV, LVOT, prox asc aorta, right PA
	Bicaval (l)	80°–110°	RA, SVC, IVC, IAS, LA
	Asc aortic short axis (o)	0°–60°	Asc aorta, SVC, PA, right PA
	Asc aortic long axis (p)	100°–150°	Asc aorta, right PA
	Desc aorta short axis (q)	0°	Desc thoracic aorta, left pleural space
Transgastric (40–45 cm)	Desc aorta long axis (r)	90°–110°	Desc thoracic aorta, left pleural space
	Basal short axis (f)	0°–20°	LV, MV, RV, TV
	Mid short axis (d)	0°–20°	LV, RV, pap mm
	Two-chamber (e)	80°–100°	LV, MV, chordae, pap mm, CS, LA
	Long axis (j)	90°–120°	LVOT, AV, MV
	RV inflow (n)	100°–120°	RV, TV, RA, TV chordae, pap mm
	Deep transgastric (45–50 cm)	Long axis (k)	0°–20° (anteflexion)

brachio v = brachiocephalic vein, PA = pulmonary artery, PV = pulmonic valve, LV = left ventricle, LA = left atrium, RV = right ventricle, RA = right atrium, MV = mitral valve, TV = tricuspid valve, IAS = interatrial septum, LAA = left atrial appendage, CS = coronary sinus, AV = aortic valve, LVOT = left ventricular outflow tract, prox = proximal, RVOT = right ventricular outflow tract, SVC = superior vena cava, IVC = inferior vena cava, RPA = right pulmonary artery, asc = ascending, desc = descending, pap mm = papillary muscles.

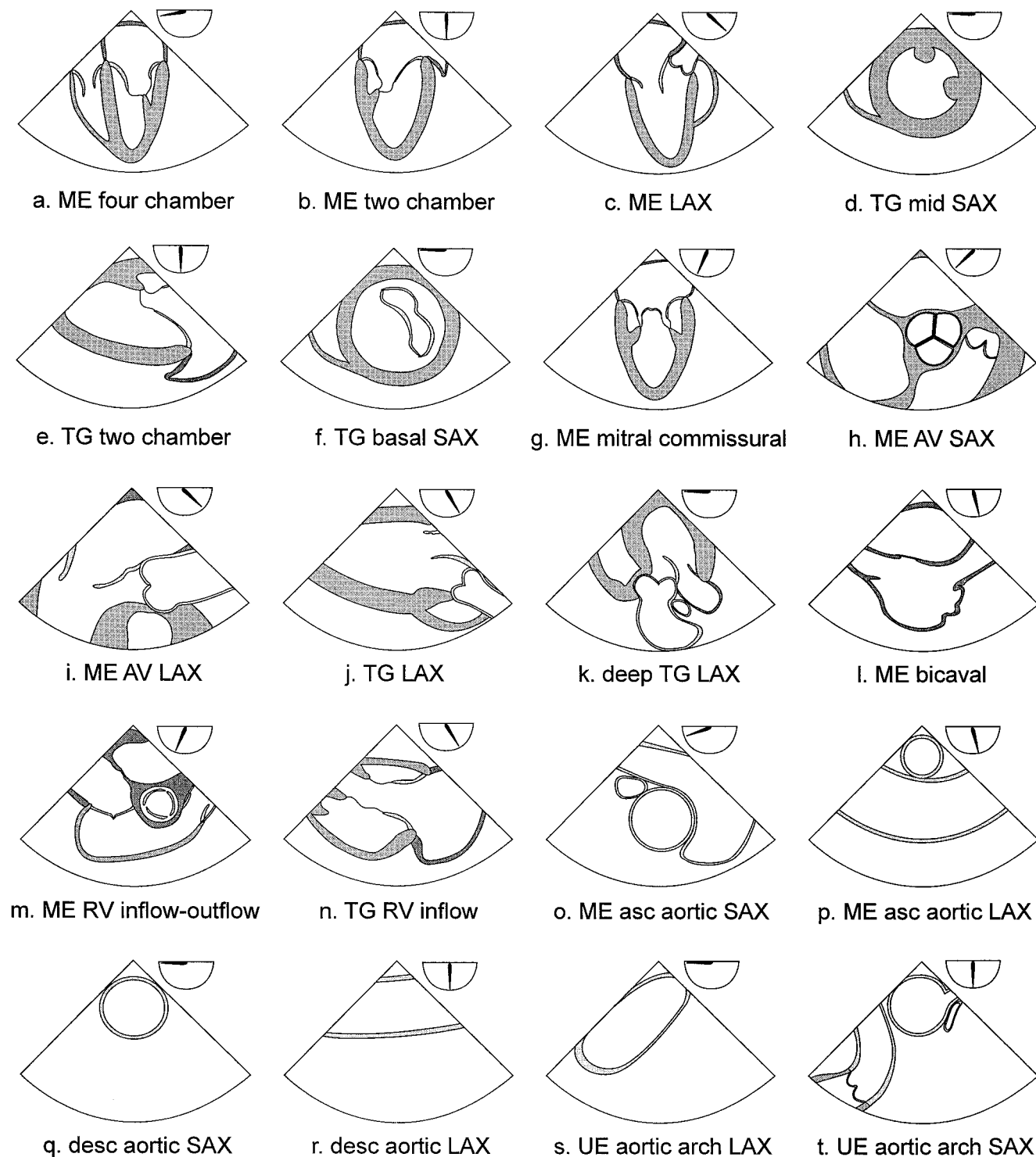
The following conventions of image display are followed in the guidelines (Figure 2). Images are displayed with the transducer location and the near field (vertex) of the image sector at the top of the display screen and the far field at the bottom. At a multipane angle of 0 degrees (the horizontal or transverse plane), with the imaging plane directed anteriorly from the esophagus through the heart, the patient's right side appears in the left of the image display (Figure 2A). Rotating the multipane angle forward to 90 degrees (vertical or longitudinal plane) moves the left side of the display inferiorly, toward the supine patient's feet (Figure 2B). Rotating the multipane angle to 180 degrees places the patient's left side to left of the display, the mirror image of 0 degrees (Figure 2C).

The comprehensive, intraoperative TEE examination recommended by the writing group consists of a series of 20 cross-sectional views of the heart and great vessels (Table 1 and Figure 3). The nomenclature is as consistent as possible with previous recommendations of the ASE Committee on Nomenclature and Standards (38) and commonly accepted terminology for transthoracic echocardiography (TTE) (39). The views are designated by the transducer location (i.e., the echo window), a description of the imaging plane (e.g., short axis, long axis), and the main anatomic structure in the image. When used without an associ-

ated structure, the term "short axis" refers to views of the LV in short axis (transgastric mid short axis view and transgastric basal short axis view). When used without an associated structure, the term "long axis" refers to views of the LV that also include the aortic valves and mitral valves (MV) (mid esophageal long axis view, transgastric long axis view, and deep transgastric long axis view). When possible, terms corresponding to the analogous TTE views are used; thus, the mid esophageal four-chamber view may be thought of as a TEE analogue of the apical four-chamber view of TTE. Table 1 also includes the typical range of probe depth and multipane angle needed to obtain each view to serve as a starting point in its acquisition. Many of the same views are also used for the CFD and spectral Doppler examination to image the flow through the chambers and valves of the heart or to obtain the velocity profiles of pulmonary venous inflow, transmitral flow, and left ventricular outflow. The writing group recognizes the complexity of any attempt to fully characterize three-dimensional structures using a limited set of two-dimensional images and acknowledges that an examination may need to include modifications or variations of the recommended cross-sections to optimally characterize an individual's anatomy or pathology.

The order in which the examination proceeds will vary from examiner to examiner. Examination of a

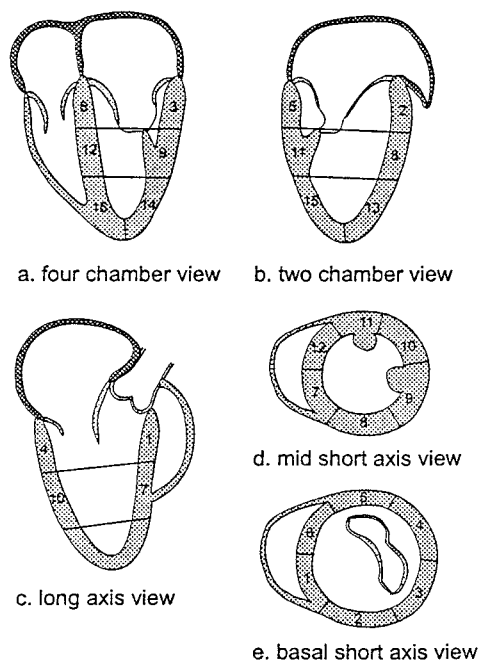




**Figure 3.** 20 cross-sectional views composing the recommended comprehensive TEE examination. Approximate multiplane angle is indicated by the icon adjacent to each view. ME = mid esophageal, LAX = long axis, TG = transgastric, SAX = short axis, AV = aortic valve, RV = right ventricle, asc = ascending, desc = descending, UE = upper esophageal.

specific structure need not be performed continuously or completed before moving on to the next structure but may be broken up into different parts of the study for greater efficiency. For example, many will find it more practical to obtain all the mid

esophageal views before proceeding to the transgastric views. In general, an intraoperative examination should begin with the structure that is the primary clinical question, often the valve or chamber being operated on. If hemodynamic instability or some

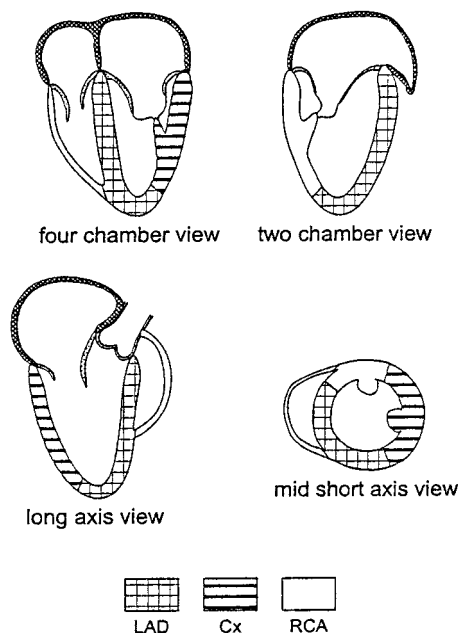


Basal Segments	Mid Segments	Apical Segments
1= Basal Anteroseptal	7= Mid Anteroseptal	13= Apical Anterior
2= Basal Anterior	8= Mid Anterior	14= Apical Lateral
3= Basal Lateral	9= Mid Lateral	15= Apical Inferior
4= Basal Posterior	10= Mid Posterior	16= Apical Septal
5= Basal Inferior	11= Mid Inferior	
6= Basal Septal	12= Mid Septal	

**Figure 4.** 16-segment model of the left ventricle. a, Four-chamber views show the three septal and three lateral segments. b, Two-chamber views show the three anterior and three inferior segments. c, Long axis views show the two anteroseptal and two posterior segments. d, Mid short axis views show all six segments at the mid level. e, Basal short axis views show all six segments at the basal level.

other interruption fragments the TEE examination, at least the main objective of the study will be accomplished. The cross-sectional views described are generally obtainable in most patients, but as a result of individual anatomic variation, not all views can be developed in all patients. Most of the structures to be examined, however, are present in more than one cross-section, permitting a complete and comprehensive examination in most patients.

The guidelines will proceed by describing the examination of the individual structures of the heart and great vessels, emphasizing the recommended cross-sections that demonstrate each particular structure. An equally valid approach is to describe each of the cross-sections, emphasizing the structures that are displayed. This conceptualization of a comprehensive intraoperative examination is represented in Table 1 and Figure 3, which list each of the cross-sectional views. In practice, performance of the examination will become a fusion of the structural and cross-sectional approaches, tailored to individual preferences and training.

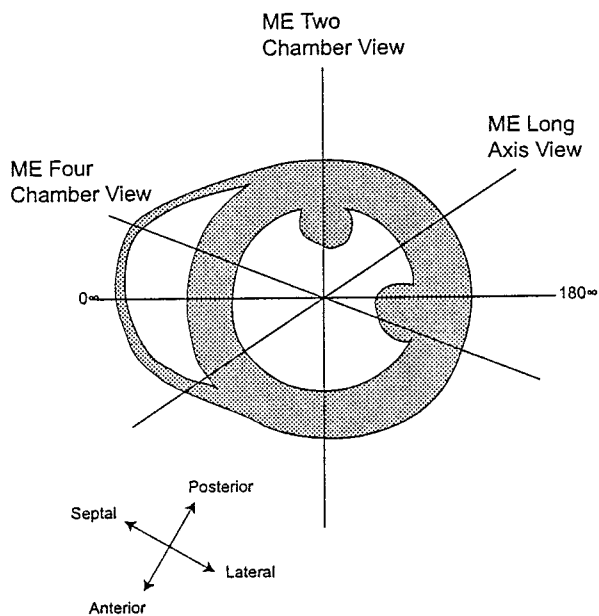


**Figure 5.** Typical regions of myocardium perfused by each of the major coronary arteries to the left ventricle. Other patterns occur as a result of normal anatomic variations or coronary disease with collateral flow. LAD = left anterior descending, Cx = circumflex, RCA = right coronary artery.

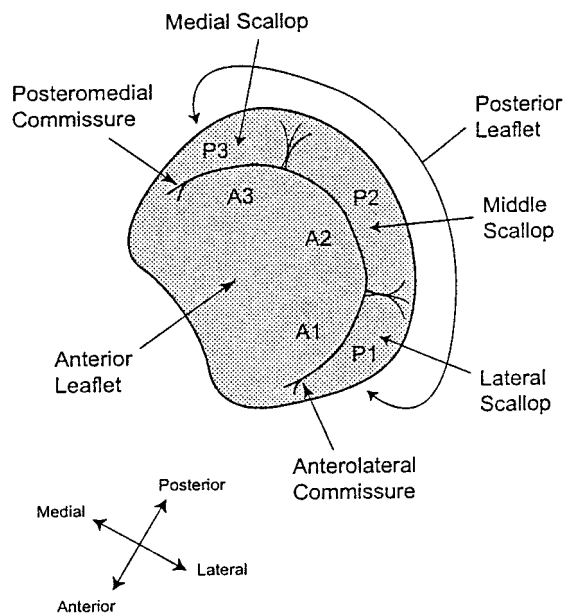
### Left Ventricle

Segmental models of the LV are needed to accurately describe the location and extent of regional wall motion abnormalities detected by echocardiography. All segmental models must balance complexity and descriptive power with practicality. The guidelines use a 16-segment model of the LV based on the recommendations of the Subcommittee on Quantification of the ASE Standards Committee (40). This model divides the LV into three levels from base to apex: basal, mid, and apical. The basal and mid levels are each divided circumferentially into six segments, and the apical level into four (Figure 4). The coronary artery that usually perfuses each segment is shown in Figure 5. In current clinical practice, analysis of LV segmental function is based on a qualitative visual assessment of the motion and thickening of a segment during systole. The recommended qualitative grading scale for wall motion is: 1 = normal (>30% thickening), 2 = mildly hypokinetic (10% to 30% thickening), 3 = severely hypokinetic (<10% thickening), 4 = akinetic (does not thicken), 5 = dyskinetic (moves paradoxically during systole). This grading scale has been used extensively in the intraoperative echocardiography literature (5,7,41-55). All 16 segments are examined by obtaining five cross-sectional views of the LV, three through the mid esophageal window and two through the transgastric window.

To obtain the mid esophageal views of the LV, the transducer is positioned posterior to the LA at the mid



**Figure 6.** Short axis drawing of the left ventricle at the mid papillary level illustrating how it is transected by the mid esophageal views. Rotating from multiplane angle 0 degrees to 180 degrees moves the imaging plane axially through the entire left ventricle. ME = mid esophageal.

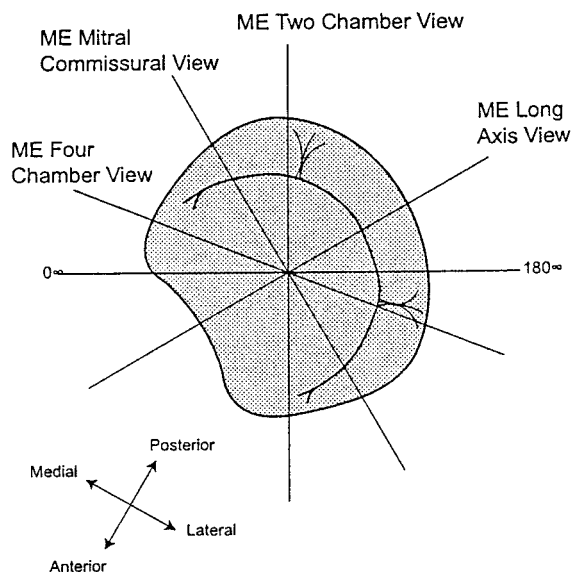


**Figure 7.** Anatomy of the mitral valve. A1 = lateral third of the anterior leaflet, A2 = middle third of the anterior leaflet, A3 = medial third of the anterior leaflet, P1 = lateral scallop of the posterior leaflet, P2 = middle scallop of the posterior leaflet, P3 = medial scallop of the posterior leaflet.

level of the MV. The imaging plane is then oriented to pass simultaneously through the center of the mitral annulus and the apex of the LV. The LV is usually oriented within the patient's chest, with its apex somewhat more inferior than the base, so the tip of the probe may require retroflexion to direct the imaging plane through the apex. The depth is adjusted to include the entire LV, usually 16 cm. The mid esophageal four-chamber view (Figure 3A) is now obtained by rotating the multiplane angle forward from 0 degrees to between 10 and 20 degrees, until the AV is no longer in view and the diameter of the tricuspid annulus is maximized. The mid esophageal four-chamber view shows the basal, mid, and apical segments in each of the septal and lateral walls (Figure 4A). The mid esophageal two-chamber view (Figure 3B) is developed by rotating the multiplane angle forward to between 80 and 100 degrees until the right atrium (RA) and right ventricle (RV) disappear. This cross-section shows the basal, mid, and apical segments in each of the anterior and inferior walls (Figure 4B). Finally, the mid esophageal long axis view (Figure 3C) is developed by rotating the multiplane angle forward to between 120 and 160 degrees, until the LV outflow tract (LVOT), AV, and the proximal ascending aorta come into view. This view shows the basal and mid anteroseptal segments, as well as the basal and mid posterior segments (Figure 4C). With the imaging plane properly oriented through the center of the mitral annulus and the LV apex, the entire LV can be examined, without moving the probe, by

simply rotating forward from 0 to 180 degrees. Figure 6 illustrates how the mid esophageal views transect the LV. It can be difficult to image the apex of the LV with TEE in some patients, especially if the LV is enlarged or has an apical aneurysm.

The transgastric views of the LV are acquired by advancing the probe into the stomach and anteflexing the tip, until the heart comes into view. At a multiplane angle of 0 degrees, a short axis view of the LV will appear, and the probe is then turned to the right or left as needed to center the LV in the display. The image depth is adjusted to include the entire LV, usually 12 cm. Next, the multiplane angle is rotated forward to 90 degrees to show the LV in long axis with the apex to the left and the mitral annulus to the right of the display. The anteflexion of the probe is adjusted until the long axis of the LV is horizontal in the display (Figure 3E). The level of the LV over which the transducer lies is noted (basal, mid, or apical), and the probe is advanced or withdrawn as needed to reach the mid papillary level. Now, the multiplane angle is rotated back to between 0 and 20 degrees, until the circular symmetry of the chamber is maximized to obtain the transgastric mid short axis view (Figure 3d). This cross-section shows the six mid level segments of the LV and has the advantage of simultaneously showing portions of the LV supplied by the right, circumflex, and left anterior descending coronary arteries and is the most popular view for monitoring LV function (Figure 5). The transgastric mid short axis view is used for assessing LV chamber size and wall thickness at end diastole, which is best determined by measuring



**Figure 8.** Short axis drawing of the mitral valve illustrating how it is transected by the mid esophageal views. Rotating from multiplane angle from 0 degrees to 180 degrees moves the imaging plane axially through the entire mitral valve. ME = mid esophageal.

at the onset of the R wave of the electrocardiogram. Normal LV short axis diameter is less than 5.5 cm, and LV wall thickness is less than 1.2 cm. End diastolic and end systolic areas of the LV chamber may be measured in this cross-section for calculation of fractional area change as an index of LV systolic function. The transgastric two-chamber view (Figure 3E) is developed by rotating the multiplane angle forward to approximately 90 degrees, until the apex and the mitral annulus come into view. The probe is turned to the left or right as needed to maximize the length of the LV chamber in the image. This view shows the basal and mid segments of the inferior and anterior walls, but usually not the apex.

The transgastric basal short axis view (Figure 3F) is obtained by withdrawing the probe from the transgastric mid short axis view until the MV appears. It shows all six basal segments of the LV. When advancing or withdrawing the probe to different ventricular levels, it is helpful to do so from the transgastric two-chamber view, which shows the position of the transducer in relation to the long axis of the LV. When the desired level is reached, the short axis view is obtained by rotating the multiplane angle back toward 0 degrees.

## Mitral Valve

The MV is composed of the anterior and posterior leaflets, chordae tendinae, papillary muscles, annulus, and LV walls. The two leaflets are joined at the anterolateral and posteromedial commissures, each of which is associated with a corresponding papillary

muscle. The posterior leaflet consists of three scallops: lateral (P1), middle (P2), and medial (P3). For descriptive purposes, the anterior leaflet is divided into three parts: lateral third (A1), middle third (A2), and medial third (A3) (Figure 7).

The MV is examined with TEE by using four mid esophageal and two transgastric views. The mid esophageal views of the MV are all developed by first positioning the transducer posterior to the mid level of the LA and directing the imaging plane through the mitral annulus parallel to the transmitral flow. Again, because the apex of the LV is located inferior to the base of the heart in many patients, retroflexion of the probe tip is often necessary. The multiplane angle is then rotated forward to develop the mid esophageal four chamber view. In this cross-section, the posterior mitral leaflet P1 is to the right of the image display, and the anterior mitral leaflet A3 is to the left. As the multiplane angle is rotated forward to about 60 degrees, a transition in the image occurs beyond which the posterior leaflet is to the left of the display, and the anterior leaflet is to the right. At this transition angle, the imaging plane is parallel to the line that intersects the two commissures of the MV, to form the mid esophageal mitral commissural view (Figure 3G). In this view, A2 is seen in the middle of the LV inflow tract with the posterior leaflet on each side; P1 is to the right of the display, and P3 is to the left. Beginning from a point where the imaging plane transects the middle of the valve, turning the probe to the right moves the plane toward the medial side of the MV through the base of the anterior leaflet, whereas turning the probe to the left moves the plane toward the lateral side through P2 of the posterior leaflet. Next, the multiplane angle is rotated forward to develop the mid esophageal two-chamber view. Now the posterior leaflet (P3) is to the left of the display and the anterior leaflet (A1) is to the right. Finally, the multiplane angle is rotated forward to the mid esophageal long axis view. In this view, the posterior mitral leaflet (P2) is to the left of the display, and the anterior mitral leaflet (A2) is to the right. As with the LV, proper orientation of the imaging plane from the mid esophageal window through the center of the mitral annulus permits the entire MV to be examined without moving the probe by rotating forward from 0 to 180 degrees, and both structures are easily examined simultaneously. Figure 8 illustrates how the mid esophageal views transect the MV.

The mid esophageal views of the MV are repeated with CFD, ensuring that the color sector includes the left atrial portion of any mitral regurgitation jet as well as the ventricular aspect of the valve to detect any flow convergence caused by mitral regurgitation. This is easily accomplished by rotating the multiplane angle backward from the mid esophageal long axis view through the two-chamber, mitral commissural and



four-chamber views. The transmitral flow velocity profile is examined using spectral pulsed wave Doppler (PWD) to evaluate LV diastolic function in the mid esophageal four-chamber or mid esophageal long axis view by placing the sample volume between the tips of the open mitral leaflets. The sample volume size is kept as small as possible (3–5 mm) and the Doppler beam aligned such that the angle between the beam and the presumed direction of transmitral flow is as close to zero as possible.

The two transgastric views of the MV are developed by advancing the probe until the transducer is level with the base of the LV. The transgastric basal short axis view provides a short axis view of the MV and is generally obtained at a multiplane angle of 0 degrees by further anteflexing the probe and withdrawing slightly to achieve a plane slightly above (superior to) the transgastric mid short axis view. Better short axis cross-sections of the MV often are obtained with the transducer slightly deeper in the stomach and with more anteflexion in order to orient the imaging plane as parallel to the mitral annulus as possible. Often, however, the cross-section obtained is not perfectly parallel to the annulus, in which case the probe is withdrawn to image the posteromedial commissure in short axis, then advanced slightly to image the anterolateral commissure. In these views of the MV, the posteromedial commissure is in the upper left of the display, the anterolateral commissure is to the lower right, the posterior leaflet is to the right of the display, and the anterior leaflet is to the left. These short axis views of the MV are very useful for determining which portion of the leaflet is abnormal or has abnormal flow. It is also important to examine the transgastric mid short axis view to detect wall motion abnormalities adjacent to the papillary muscles or hypermobility at the papillary muscles indicating rupture of the papillary muscle or its components. The transgastric two-chamber view is developed from the same probe position by rotating the multiplane angle forward to about 90 degrees and is especially useful for examining the chordae tendinae, which are perpendicular to the ultrasound beam in this view. The chordae to the posteromedial papillary muscle are at the top of the display, and those to the anterolateral papillary muscle are at the bottom. Both of the transgastric views of the MV are repeated using CFD.

## Aortic Valve, Aortic Root, and Left Ventricular Outflow Tract

The AV is a semilunar valve with three cusps located close to the center of the heart. The aortic root is not a specific structure, *per se*, but includes the AV annulus, cusps, sinuses of Valsalva, coronary artery ostia, sinotubular junction, and proximal ascending aorta. The LVOT is the outflow portion of the LV just inferior to

the AV. All these structures are examined in detail with TEE by using four cross-sections.

The mid esophageal AV short axis view (Figure 3h) is obtained from the mid esophageal window by advancing or withdrawing the probe until the AV comes into view and then turning the probe to center the AV in the display. The image depth is adjusted to between 10 and 12 cm to position the AV in the middle of the display. Next, the multiplane angle is rotated forward to approximately 30 to 60 degrees until a symmetrical image of all three cusps of the aortic valve comes into view. This cross-section is the only view that provides a simultaneous image of all three cusps of the AV. The cusp adjacent to the atrial septum is the noncoronary cusp, the most anterior cusp is the right coronary cusp, and the other is the left coronary cusp. The probe is withdrawn or anteflexed slightly to move the imaging plane superiorly through the sinuses of Valsalva to bring the right and left coronary ostia and then the sinotubular junction into view. The probe is then advanced to move the imaging plane through and then proximal to the AV annulus to produce a short axis view of the LVOT. The mid esophageal AV short axis view at the level of the AV cusps is used to measure the length of the free edges of the AV cusps and the area of the AV orifice by planimetry. CFD is applied in this cross-section to detect aortic regurgitation and estimate the size and location of the regurgitant orifice.

The mid esophageal AV long axis view (Figure 3i) is developed by keeping the AV in the center of the display while rotating forward to a multiplane angle of 120 to 160 degrees until the LVOT, AV, and proximal ascending aorta line up in the image. The LVOT appears toward the left of the display and the proximal ascending aorta toward the right. The cusp of the AV that appears anteriorly or toward the bottom of the display is always the right coronary cusp, but the cusp that appears posteriorly in this cross-section may be the left or the noncoronary cusp, depending on the exact location of the imaging plane as it passes through the valve. The mid esophageal AV long axis view is the best cross-section for assessing the size of the aortic root by measuring the diameters of the AV annulus, sinuses of Valsalva, sinotubular junction, and proximal ascending aorta, adjusting the probe to maximize the internal diameter of these structures. The diameter of the AV annulus is measured during systole at the points of attachment of the aortic valve cusps to the annulus and is normally between 1.8 and 2.5 cm. The mid esophageal AV long axis view is repeated with CFD to assess flow through the LVOT, AV, and proximal ascending aorta and is especially useful for detecting and quantifying aortic regurgitation.

The primary purpose of the two transgastric views of the AV is to direct a Doppler beam parallel to flow through the AV, which is not possible from the mid

esophageal window. They also provide good images of the ventricular aspect of the AV in some patients. The transgastric long axis view (Figure 3j) is developed from the transgastric mid short axis view by rotating the multiplane angle forward to 90 to 120 degrees until the AV comes into view in the right side of the far field. Sometimes, turning the probe slightly to the right is necessary to bring the LVOT and AV into view.

The deep transgastric view is obtained by advancing the probe deep into the stomach and positioning the probe adjacent to the LV apex. The probe is then anteflexed until the imaging plane is directed superiorly toward the base of the heart, developing the deep transgastric long axis view (Figure 3K). The exact position of the probe and transducer is more difficult to determine and control deep in the stomach, but some trial and error flexing, turning, advancing, withdrawing, and rotating of the probe develops this view in most patients. In the deep transgastric long axis view, the aortic valve is located in the far field at the bottom of the display with the LV outflow directed away from the transducer. Detailed assessment of valve anatomy is difficult in this view because the LVOT and AV are so far from the transducer, but Doppler quantification of flow velocities through these structures is usually possible. Multiplane rotation from this cross-section can achieve images of the aortic arch and great vessels in the far field in some patients.

Doppler quantification of blood flow velocities through the LVOT and AV are performed using the transgastric long axis view or the deep transgastric long axis view. Blood flow velocity in the LVOT is measured by positioning the PWD sample volume in the center of the LVOT just proximal to the AV. Flow velocity through the AV is measured by directing the CWD beam through the LVOT and across the valve cusps. Normal LVOT and AV flow velocities are less than 1.5 m/s. CFD imaging of the LVOT and AV is useful for in directing the Doppler beam through the area of maximum flow when making these velocity measurements.

### **Left Atrium, Left Atrial Appendage, Pulmonary Veins, and Atrial Septum**

Given its anatomic location immediately anterior to the esophagus, the LA is the cardiac chamber that is most consistently and easily imaged. Examination of the LA is initiated with the mid esophageal four-chamber view with the image depth adjusted to approximately 10 cm to maximize the LA size in the display. Withdrawing and advancing the probe several centimeters generates images of the entire LA from its most superior to inferior extent. Near its superior and lateral aspect, the LA is seen to join the

left atrial appendage (LAA). The left upper pulmonary vein (LUPV), which enters the LA just lateral to the LAA from an anterior to posterior trajectory, is identified by withdrawing slightly and turning the probe to the left. The left lower pulmonary vein (LLPV) is then identified by turning slightly farther to the left and advancing 1 to 2 cm. The LLPV enters the LA just below the LUPV, courses in a more lateral to medial direction, and is less suitable for Doppler quantification of pulmonary venous blood flow velocity being nearly perpendicular to the ultrasound beam. In some patients, the LUPV and LLPV join and enter the LA as a single vessel. The right upper pulmonary vein (RUPV) is imaged by turning the probe to the right at the level of the LAA. Like the LUPV, the RUPV can be seen entering the LA in an anterior to posterior direction. The right lower pulmonary vein, which enters the LA nearly at a right angle to the Doppler beam, is then located by advancing the probe 1 to 2 cm and turning slightly to the right. The interatrial septum (IAS) is examined next at the mid esophageal level by turning the probe slightly to the right of midline and advancing and withdrawing the probe through its entire superior-inferior extent. The IAS consists of the thin fossa ovalis centrally and thicker limbus regions anteriorly and posteriorly. The IAS is examined with CFD to detect interatrial shunts. Decreasing the scale (Nyquist limit) of the CFD is useful for detecting low velocity flow through an atrial septal defect or patent foramen ovale. Ten milliliters of saline agitated with a small amount of air (less than ¼ mL) can be injected into the RA as positive airway pressure is released to detect interatrial shunt as well, looking for the appearance of contrast in the LA in fewer than five cardiac cycles.

From the mid esophageal four-chamber view, the multiplane angle is rotated forward to approximately 90 degrees to the mid esophageal two-chamber view to obtain orthogonal images of the LA. In this cross-section, the LA is examined from its left to right limits by turning the probe from side to side. The LAA is seen as an outpouching of the lateral, superior aspect of the LA. From there, the LUPV is identified by turning the probe slightly farther to the left. The mid esophageal bicaval view (Figure 3l) is developed from the mid esophageal two chamber view by turning the probe to the right and rotating the multiplane angle forward to between 80 and 110 degrees until both the superior vena cava (SVC) and the inferior vena cava (IVC) come into view. The mid esophageal bicaval view generally provides an excellent view of the IAS as well as the body and appendage of the RA and the vena cavae. It is repeated with CFD to detect flow across the IAS. Finally, the probe is turned slightly farther to the right to reveal the RUPV entering the LA.

The pulmonary venous inflow velocity profile is examined by placing the PWD sample volume into any of the pulmonary veins 0.5 to 1.0 cm proximal to the LA. The LUPV is usually the easiest to identify and the most parallel to the Doppler beam. CFD imaging is useful in locating pulmonary venous flow and aligning the Doppler beam parallel to its direction, decreasing the scale (Nyquist limit) to 20–30 cm/s to detect the lower velocity venous flow.

## Right Ventricle

The RV consists of the free wall, the septal wall, and the RV outflow tract (RVOT), which enclose an asymmetrical, crescent shaped cavity. The septal wall is shared with the LV, so echocardiographic assessment of its regional function uses the segmental model described for the LV. A formal segmental scheme for the RV free wall has not been established, but the terms basal, apical, anterior, inferior, and RVOT may be used to localize specific regions of the wall. The free wall of the RV is thinner than that of the LV, normally less than 5 mm at end diastole. Because of the asymmetry of the RV geometry and reduced muscular mass compared with the LV, the contractile amplitude of the RV is less than that seen with the LV, so subtle regional dysfunction is more difficult to diagnose, requiring either akinesia or dyskinesia to establish a clear diagnosis of regional dysfunction. The shape of the RV cavity in short-axis provides information regarding RV function. The septal wall of the RV is normally convex toward the crescent shaped RV cavity. RV pressure or volume overload can cause flattening or leftward deviation of the septal wall, producing an elliptical or circular short-axis shape of the RV cavity.

The examination of the RV begins with the mid esophageal four chamber view. The probe is then turned to the right until the tricuspid valve (TV) is in the center of the display. The image depth is adjusted to include the tricuspid annulus and RV apex. This cross-section shows the apical portion of the anterior RV free wall to the right of the display and the basal anterior free wall to the left. The mid esophageal RV inflow-outflow view (Figure 3M) is developed by rotating the multiplane angle forward to between 60 and 90 degrees keeping the TV visible until the RVOT opens up and the pulmonic valve (PV) and main pulmonary artery (PA) come into view. This cross-section shows the RVOT to the right side of the display and the inferior (diaphragmatic) portion of the RV free wall to the left.

In the transgastric mid short axis view, the RV is seen to the left side of the Display from the LV. The transgastric RV inflow view (Figure 3N) is developed from this view by turning the probe to the right until

the RV cavity is located in the center of the display and rotating the multiplane angle forward to between 100 and 120 degrees until the apex of the RV appears in the left side of the display. This cross-section provides good views of the inferior (diaphragmatic) portion of the RV free wall, located in the near field. In many patients, adjusting the multiplane angle toward 0 degrees and anteflexing the probe from the transgastric RV inflow view can produce images of the RVOT and PV.

## Tricuspid Valve

The TV is composed of three leaflets (anterior, posterior, and septal), chordae tendinae, papillary muscles, annulus, and RV walls. It is examined with the same cross-sections used to examine the RV. In the mid esophageal four-chamber view, the TV is seen with the septal leaflet to the right of the display and the posterior leaflet to the left. The probe is advanced and withdrawn to move the imaging plane through the tricuspid annulus from its inferior to superior extent. Next, keeping the tricuspid annulus in the center of the display, the multiplane angle is rotated forward to develop the mid esophageal RV inflow-outflow view that shows the posterior leaflet of the TV to the left side of the display and the anterior leaflet of the TV to the right. These views are repeated with CFD to detect flow abnormalities of the TV.

The transgastric views of the TV are obtained by advancing the probe into the stomach and developing the transgastric RV inflow view as previously described. This cross-section shows the TV in the middle of the display with the RV to the left and the RA to the right. This view also usually provides the best images of the tricuspid chordae tendinae because they are perpendicular to the ultrasound beam. A short axis view of the TV is developed by withdrawing the probe slightly toward the base of the heart until the tricuspid annulus is in the center of the display and rotating the multiplane angle backwards to about 30 degrees. In this cross-section the anterior leaflet of the TV is to the left in the far field, the posterior leaflet is to the left in the near field, and the septal leaflet is to the right side of the display. These views are repeated with CFD of the valve.

## Right Atrium

The examination of the RA is initiated from the mid esophageal four-chamber view which allows direct comparison of the relative sizes of the right and left atria. The probe is turned to the right to bring the RA into the center of the display and the image depth adjusted to maximize the size of the RA in the display.



The probe is then advanced and withdrawn to examine its entire inferior to superior extent. The mid esophageal bicaval view is next developed by rotating the multiplane angle forward to between 80 and 110 degrees until the SVC appears in the right side of the display and the IVC in the left. This view also provides good images of the right atrial appendage, seen to emanate from the superior, anterior aspect of the RA. The probe is turned to the right and the left from the medial to the lateral borders of the RA to complete the exam.

The RA wall is typically thinner than the LA. The Eustachian valve, a normal structure of variable size, is seen at the junction of the IVC and the RA. It is formed by a fold of endocardium that arises from the lower end of the crista terminalis and stretches across the posterior margin of the IVC to become continuous with the border of the fossa ovalis. Occasionally, the Eustachian valve has mobile, serpiginous filaments attached to it, termed the Chiari network, which is considered to be a normal variant (56). From the mid esophageal four-chamber view the IVC and SVC are examined by advancing or withdrawing the probe from their junctions with the RA to their more proximal portions. If present, central venous catheters or pacemaker electrodes entering the RA from the SVC can be seen with the mid esophageal bicaval view.

## Coronary Sinus

The coronary sinus is located in the atrioventricular groove along the posterior surface of the heart and empties into the RA at the most inferior and posterior extent of the atrial septum adjacent to the septal leaflet of the TV. It is imaged in long axis by slightly advancing or retroflexing the probe from the mid esophageal four-chamber view to move the imaging plane through the inferior wall of the LA. A short axis image of the coronary sinus is seen in the mid esophageal two-chamber view to the left of the display in or just superior to the atrioventricular groove. Withdrawing the probe from the transgastric basal short axis view until the coronary sinus appears in long axis is another approach to imaging this structure.

## Pulmonic Valve and Pulmonary Artery

Like the AV, the PV is a trileaflet, semilunar valve. Its leaflets, however, are thinner and farther from the esophagus, and therefore more difficult to image with TEE. The orientation of flow through the PV is roughly perpendicular to flow through the AV and directed from anteriorly to posteriorly and slightly from the patient's right to left. TEE views of the PV are made from three cross-sections. The mid esophageal AV short axis view provides a view of the PV and

main PA to the right side of the display. The multiplane angle is rotated back toward 0 degrees and the probe ante-flexed or withdrawn slightly to display the bifurcation of the main pulmonary artery with the right PA at the top of the display coursing off to the patient's right. The left PA arches over the left mainstem bronchus after bifurcating from the main PA and is often difficult to visualize with TEE as the airway comes between it and the esophagus. The mid esophageal RV inflow-outflow view displays the PV in long-axis and is useful for detecting pulmonic regurgitation by CFD. The main PA and the PV are seen in the upper esophageal aortic arch short axis view (Figure 3T, see below for description of view) in the left side of the display by turning the probe until these structures come into view. Retroflexing the probe will often improve the view of the PV. The upper esophageal aortic arch short axis view usually allows the Doppler beam to be aligned parallel to flow through the PV and main PA and is therefore useful for measuring blood flow velocities through these structures.

## Thoracic Aorta

Most of the thoracic aorta can be routinely imaged with multiplane TEE because it is adjacent to the esophagus as it passes vertically through the mediastinum. However, because the air filled trachea is interposed between the esophagus and the distal ascending aorta and proximal aortic arch, these regions usually cannot be visualized with TEE (57). Epi-aortic scanning can be used to examine these areas through a median sternotomy by covering a high frequency transducer with a sterile sheath and placing it directly on the ascending aorta in the surgical field.

The proximal and mid ascending aorta is seen with TEE through the proximal portion of the mid esophageal window with a probe depth of approximately 30 cm from the incisors, placing the transducer at the level of the right pulmonary artery. The mid esophageal ascending aortic short axis view (Figure 3O) is developed by locating the ascending aorta in the center of the image and adjusting the multiplane angle until the vessel appears circular, usually between 0 and 60 degrees. The probe is advanced and withdrawn in the esophagus to examine different levels of the aorta. The multiplane angle is rotated forward to between 100 and 150 degrees to develop the mid esophageal ascending aortic long axis view (Figure 3P), in which the anterior and posterior walls of the aorta appear parallel to one another. The diameter of the ascending aorta at the sinotubular junction and at specified distances from the sinotubular junction or the AV annulus is measured from the long axis and short axis images.

TEE examination of the descending thoracic aorta is accomplished by turning the probe to the left from the



mid esophageal four-chamber view until the circular, short axis image of the vessel is located in the center of the near field of the display producing the descending aortic short axis view (Figure 3Q). The image depth is decreased to 6 to 8 cm to increase the size of the aorta in the display and the focusing depth moved to the near field to optimize image quality. The multiplane angle is rotated forward from 0 to between 90 and 110 degrees to yield circular, oblique, and eventually the descending aortic long axis view (Figure 3R) in which the walls of the descending aorta appear as two parallel lines. The entire descending thoracic aorta and upper abdominal aorta are examined by advancing and withdrawing the probe within the esophagus. The esophagus is located anterior to the aorta at the level of the diaphragm and then winds around within the thorax until it is posterior to the aorta at the level of the distal arch. As the probe is advanced within the esophagus starting from the distal arch, it is turned to the left (posteriorly) to keep the descending aorta in view. The mid and distal abdominal aorta usually are not seen because it is difficult to maintain contact between the transducer and the aorta within the stomach.

Because of the changing relationship between the esophagus and the descending thoracic aorta and lack of internal anatomic landmarks, it is difficult to designate anterior and posterior or right to left orientations of the descending thoracic aorta in the TEE images. One approach to anatomically localize abnormalities within the descending thoracic aorta is to describe the location of the defect as a distance from the origin of the left subclavian artery and its location on the vessel wall relative to the position of the esophagus (e.g., the wall opposite the esophagus). Another approach is to record the depth of the lesion from the incisors. The presence of an adjacent structure, such as the LA or the base of the LV, may also designate a level within the descending aorta.

The aortic arch is imaged with the multiplane angle at 0 degrees by withdrawing the probe while maintaining an image of the descending thoracic aorta until the upper esophageal window is reached, at approximately 20 to 25 cm from the incisors, to develop the upper esophageal aortic arch long axis view (Figure 3S). Because the mid aortic arch lies anterior to the esophagus, as the tip of the probe is withdrawn farther, it needs to be turned to the right (anterior) to keep the vessel in view. The proximal arch is to the left of the display and the distal arch to the right. The multiplane angle is rotated forward to 90 degrees to develop the upper esophageal aortic arch short axis view (Figure 3T), and the probe is turned to the right to move the imaging plane proximally through the arch and to the left to move distally.

In some individuals, withdrawing the transducer farther from the upper esophageal aortic arch long

axis view can image the proximal left subclavian artery and left carotid artery. The right brachiocephalic artery is more difficult to image because of the interposition of the air filled trachea. As the transducer is withdrawn, it is turned to the left to follow the left subclavian artery distally. The left internal jugular vein lies anterior to and to the left of the common carotid artery and sometimes is seen. In the upper esophageal aortic arch short axis view the origin of the great vessels often is identified at the superior aspect of the arch to the right of the display. The visualization rate of the arch vessels by TEE is lowest for the right brachiocephalic artery and highest for the left subclavian. The left brachiocephalic vein is also often seen anterior to the arch in views of the aortic arch.

## Conclusion

Recent advances in echocardiographic instrumentation have increased the diagnostic capabilities of TEE, but have also increased the number of possible approaches for performing a routine TEE examination. Guidelines recommending a methodology for performing a comprehensive intraoperative multiplane TEE examination based on a series of 20 anatomically referenced cross-sectional images are described to promote training in TEE, assist assessment of quality and completeness of individual studies, and facilitate comparison of studies performed at different centers. When possible, the cross-sectional imaging planes were chosen to correspond to those used in transthoracic echocardiography, and an effort was made to choose nomenclature consistent with the recommendations of the ASE Committee on Nomenclature and Standards. We hope that acceptance of a format for performing, acquiring, and archiving intraoperative multiplane TEE examinations will promote a more objective approach to describing the echocardiographic findings that are used to make management decisions and increase the benefit that can be achieved with TEE in the operating room.

## References

1. Matsumoto M, Oka Y, Strom J, et al. Application of transesophageal echocardiography to continuous intraoperative monitoring of left ventricular performance. *Am J Cardiol* 1980;46:95-105.
2. Deleted in proof.
3. Dubroff JM, Clark MB, Wong CY, et al. Left ventricular ejection fraction during cardiac surgery: a two-dimensional echocardiographic study. *Circulation* 1983;68:95-103.
4. Beaupre PN, Kremer PF, Cahalan MK, et al. Intraoperative detection of changes in left ventricular segmental wall motion by transesophageal two-dimensional echocardiography. *Am Heart J* 1984;107:1021-3.
5. Smith JS, Cahalan MK, Benefiel DJ, et al. Intraoperative detection of myocardial ischemia in high-risk patients: electrocardiography versus two-dimensional transesophageal echocardiography. *Circulation* 1985;72:1015-21.

6. Thys DM, Hillel Z, Goldman ME, et al. A comparison of hemodynamic indices derived by invasive monitoring and two-dimensional echocardiography. *Anesthesiology* 1987;67:630-4.
7. Leung JM, O'Kelly B, Browner WS, et al. Prognostic importance of postbypass regional wall-motion abnormalities in patients undergoing coronary artery bypass graft surgery. SPI Research Group. *Anesthesiology* 1989;71:16-25.
8. van Daele ME, Sutherland GR, Mitchell MM, et al. Do changes in pulmonary capillary wedge pressure adequately reflect myocardial ischemia during anesthesia? A correlative preoperative hemodynamic, electrocardiographic, and transesophageal echocardiographic study. *Circulation* 1990;81:865-71.
9. Ungerleider RM, Greeley WJ, Sheikh KH, et al. Routine use of intraoperative epicardial echocardiography and Doppler color flow imaging to guide and evaluate repair of congenital heart lesions: a prospective study. *J Thorac Cardiovasc Surg* 1990;100:297-309.
10. Stanley TE 3d, Rankin JS. Idiopathic hypertrophic subaortic stenosis and ischemic mitral regurgitation: the value of intraoperative transesophageal echocardiography and Doppler color flow imaging in guiding operative therapy. *Anesthesiology* 1990;72:1083-5.
11. Sheikh KH, de Bruijn NP, Rankin JS, et al. The utility of transesophageal echocardiography and Doppler color flow imaging in patients undergoing cardiac valve surgery. *J Am Coll Cardiol* 1990;15:363-72.
12. Black S, Muzzi DA, Nishimura RA, Cucchiara RF. Preoperative and intraoperative echocardiography to detect right-to-left shunt in patients undergoing neurosurgical procedures in the sitting position. *Anesthesiology* 1990;72:436-8.
13. Grigg LE, Wigle ED, Williams WG, et al. Transesophageal Doppler echocardiography in obstructive hypertrophic cardiomyopathy: clarification of pathophysiology and importance in intraoperative decision making. *J Am Coll Cardiol* 1992;20:42-52.
14. Marwick TH, Stewart WJ, Currie PJ, Cosgrove DM. Mechanisms of failure of mitral valve repair: an echocardiographic study. *Am Heart J* 1991;122:149-56.
15. Sheikh KH, Bengtson JR, Rankin JS, et al. Intraoperative transesophageal Doppler color flow imaging used to guide patient selection and operative treatment of ischemic mitral regurgitation. *Circulation* 1991;84:594-604.
16. Troianos CA, Savino JS, Weiss RL. Transesophageal echocardiographic diagnosis of aortic dissection during cardiac surgery. *Anesthesiology* 1991;75:149-53.
17. Porembka DT, Johnson DJ 2d, Hoit BD, et al. Penetrating cardiac trauma: a perioperative role for transesophageal echocardiography. *Anesth Analg* 1993;77:1275-7.
18. Troianos CA, Stypula RW Jr. Transesophageal echocardiographic diagnosis of pulmonary artery catheter entrapment and coiling. *Anesthesiology* 1993;79:602-4.
19. Stevenson JG, Sorensen GK, Gartman DM, et al. Transesophageal echocardiography during repair of congenital cardiac defects: identification of residual problems necessitating reoperation. *J Am Soc Echocardiogr* 1993;6:356-65.
20. Darmon PL, Hillel Z, Mogtader A, et al. Cardiac output by transesophageal echocardiography using continuous-wave Doppler across the aortic valve. *Anesthesiology* 1994;80:796-805.
21. Shanewise JS, Sadel SM. Intraoperative transesophageal echocardiography to assist the insertion and positioning of the intraaortic balloon pump. *Anesth Analg* 1994;79:577-80.
22. Cheung AT, Savino JS, Weiss SJ, et al. Echocardiographic and hemodynamic indexes of left ventricular preload in patients with normal and abnormal ventricular function. *Anesthesiology* 1994;81:376-87.
23. Ungerleider RM, Kisslo JA, Greeley WJ, et al. Intraoperative echocardiography during congenital heart operations: experience from 1,000 cases. *Ann Thorac Surg* 1995;60:S539-42.
24. Hartman GS, Yao FS, Bruefach M 3rd, et al. Severity of aortic atheromatous disease diagnosed by transesophageal echocardiography predicts stroke and other outcomes associated with coronary artery surgery: a prospective study. *Anesth Analg* 1996;83:701-8.
25. Perrino AC Jr, Harris SN, Luther MA. Intraoperative determination of cardiac output using multiplane transesophageal echocardiography: a comparison to thermodilution. *Anesthesiology* 1998;89:350-7.
26. Practice guidelines for perioperative transesophageal echocardiography. A report by the American Society of Anesthesiologists and the Society of Cardiovascular Anesthesiologists Task Force on Transesophageal Echocardiography. *Anesthesiology* 1996;84:986-1006.
27. Yvorchuk KY, Sochowski RA, Chan KL. A prospective comparison of the multiplane probe with the biplane probe in structure visualization and Doppler examination during transesophageal echocardiography. *J Am Soc Echocardiogr* 1995;8:111-20.
28. Faletra F, De Chiara F, Corno R, Passini L. Additional diagnostic value of multiplane echocardiography over biplane imaging in assessment of mitral prosthetic valves. *Heart* 1996;75:609-13.
29. Warner JG Jr, Nomeir AM, Salim M, Kitzman DW. A prospective, randomized, blinded comparison of multiplane and biplane transesophageal echocardiographic techniques. *J Am Soc Echocardiogr* 1996;9:865-73.
30. Pepi M, Barbier P, Doria E, et al. Intraoperative multiplane vs biplane transesophageal echocardiography for the assessment of cardiac surgery. *Chest* 1996;109:305-11.
31. Kim KS, Macted W, Nanda NC, et al. Comparison of multiplane and biplane transesophageal echocardiography in the assessment of aortic stenosis. *Am J Cardiol* 1997;79:436-41.
32. Daniel WG, Erbel R, Kasper W, et al. Safety of transesophageal echocardiography: a multicenter survey of 10,419 examinations. *Circulation* 1991;83:817-21.
33. Savino JS, Hanson CW 3rd, Bigelow DC, et al. Oropharyngeal injury after transesophageal echocardiography. *J Cardiothorac Vasc Anesth* 1994;8:76-8.
34. Spahn DR, Schmid S, Carrel T, et al. Hypopharynx perforation by a transesophageal echocardiography probe. *Anesthesiology* 1995;82:581-3.
35. Latham P, Hodgins LR. A gastric laceration after transesophageal echocardiography in a patient undergoing aortic valve replacement. *Anesth Analg* 1995;81:641-2.
36. Kharasch ED, Sivarajan M. Gastroesophageal perforation after intraoperative transesophageal echocardiography. *Anesthesiology* 1996;85:426-8.
37. Chow MS, Taylor MA, Hanson CW 3rd. Splenic laceration associated with transesophageal echocardiography. *J Cardiothorac Vasc Anesth* 1998;12:314-6.
38. Henry WL, DeMaria A, Gramiak R, et al. Report of the American Society of Echocardiography committee on nomenclature and standards in two-dimensional echocardiography. *Circulation* 1980;62:212-5.
39. Weyman AE. Standard plane positions-standard imaging planes. In: Weyman AE, ed. Principles and practice of echocardiography. Philadelphia: Lea & Febiger, 1994:98-123.
40. Schiller NB, Shah PM, Crawford M, et al. Recommendations for quantitation of the left ventricle by two-dimensional echocardiography. American Society of Echocardiography Committee on Standards, Subcommittee on Quantitation of Two-Dimensional Echocardiograms. *J Am Soc Echocardiogr* 1989;2:358-67.
41. Helman JD, Leung JM, Bellows WH, et al. The risk of myocardial ischemia in patients receiving desflurane versus sufentanil anesthesia for coronary artery bypass graft surgery. The S.P.I. Research Group. *Anesthesiology* 1992;77:47-62.
42. Eisenberg MJ, London MJ, Leung JM, et al. Monitoring for myocardial ischemia during noncardiac surgery. A technology assessment of transesophageal echocardiography and 12-lead electrocardiography. The Study of Perioperative Ischemia Research. *JAMA* 1992;268:210-6.

43. Leung JM, Stanley T 3rd, Mathew J, et al. An initial multicenter, randomized controlled trial on the safety and efficacy of acadesine in patients undergoing coronary artery bypass graft surgery. SPI Research Group. *Anesth Analg* 1994;78:420-34.
44. Catoire P, Saada M, Liu N, et al. Effect of preoperative normovolemic hemodilution on left ventricular segmental wall motion during abdominal aortic surgery. *Anesth Analg* 1992;75:654-9.
45. Leung JM, Goehner P, O'Kelly BF, et al. Isoflurane anesthesia and myocardial ischemia: comparative risk versus sufentanil anesthesia in patients undergoing coronary artery bypass graft surgery. The SPI (Study of Perioperative Ischemia) Research Group. *Anesthesiology* 1991;74:838-47.
46. Leung JM, O'Kelly BF, Mangano DT. Relationship of regional wall motion abnormalities to hemodynamic indices of myocardial oxygen supply and demand in patients undergoing CABG surgery. *Anesthesiology* 1990;73:802-14.
47. London MJ, Tubau JF, Wong MG, et al. The "natural history" of segmental wall motion abnormalities in patients undergoing noncardiac surgery. S.P.I. Research Group. *Anesthesiology* 1990;73:644-55.
48. Cahalan MK, Prakash O, Rulf EN, et al. Addition of nitrous oxide to fentanyl anesthesia does not induce myocardial ischemia in patients with ischemic heart disease. *Anesthesiology* 1987;67:925-9.
49. Smith JS, Roizen MF, Cahalan MK, et al. Does anesthetic technique make a difference? Augmentation of systolic blood pressure during carotid endarterectomy: effects of phenylephrine versus light anesthesia and of isoflurane versus halothane on the incidence of myocardial. *Anesthesiology* 1988;69:846-53.
50. Mitchell MM, Prakash O, Rulf EN, et al. Nitrous oxide does not induce myocardial ischemia in patients with ischemic heart disease and poor ventricular function. *Anesthesiology* 1989;71:526-34.
51. Rulf EN, Prakash O, Polak PE, et al. The incidence of myocardial ischaemia with moderate doses of fentanyl and sufentanil. *J Cardiothorac Anesth* 1989;3:6.
52. Eger EI 2d, Lampe GH, Wauk LZ, et al. Clinical pharmacology of nitrous oxide: an argument for its continued use. *Anesth Analg* 1990;71:575-85.
53. Seeberger MD, Cahalan MK, Chu E, et al. Rapid atrial pacing for detecting provokable demand ischemia in anesthetized. *Anesth Analg* 1997;84:1180-5.
54. Seeberger MD, Cahalan MK, Rouine-Rapp K, et al. Acute hypovolemia may cause segmental wall motion abnormalities in the absence of myocardial ischemia. *Anesth Analg* 1997;85:1252-7.
55. Rouine-Rapp K, Ionescu P, Balea M, et al. Detection of intraoperative segmental wall-motion abnormalities by transesophageal echocardiography: the incremental value of additional cross sections in the transverse and longitudinal planes. *Anesth Analg* 1996;83:1141-8.
56. Cujec B, Mycyk T, Khouri M. Identification of Chiari's network with transesophageal echocardiography. *J Am Soc Echocardiogr* 1992;5:96-9.
57. Konstadt SN, Reich DL, Quintana C, Levy M. The ascending aorta: how much does transesophageal echocardiography see? *Anesth Analg* 1994;78:240-4.