

Clinical guidelines on central venous catheterisation

P. FRYKHOLM¹, A. PIKWER², F. HAMMARSKJÖLD^{3,4}, A. T. LARSSON⁵, S. LINDGREN⁶, R. LINDWALL⁷, K. TAXBRO³, F. ÖBERG⁸, S. ACOSTA⁹ and J. ÅKESON²

¹Department of Surgical Sciences, Anaesthesiology and Intensive Care Medicine, University Hospital, Uppsala University, Uppsala, Sweden, ²Department of Clinical Sciences Malmö, Anaesthesiology and Intensive Care Medicine, Skåne University Hospital, Lund University, Malmö, Sweden, ³Department of Anaesthesiology and Intensive Care Medicine, Ryhov County Hospital, Jönköping, Sweden, ⁴Division of Infectious Diseases, Department of Clinical and Experimental Medicine, Faculty of Health Sciences, Linköping University, Linköping, Sweden, ⁵Department of Anaesthesiology and Intensive Care Medicine, Gävle-Sandviken County Hospital, Gävle, Sweden, ⁶Department of Anaesthesiology and Intensive Care Medicine, Institute of Clinical Sciences, Sahlgrenska Academy, University of Gothenburg, Gothenburg, Sweden, ⁷Department of Clinical Sciences, Division of Anaesthesiology and Intensive Care Medicine, Karolinska Institute, Danderyd University Hospital, Stockholm, Sweden, ⁸Department of Anaesthesiology and Intensive Care Medicine, Karolinska University Hospital Solna, Stockholm, Sweden and ⁹Department of Clinical Sciences Malmö, Vascular Centre, Skåne University Hospital, Lund University, Malmö, Sweden

Safe and reliable venous access is mandatory in modern health care, but central venous catheters (CVCs) are associated with significant morbidity and mortality. This paper describes current Swedish guidelines for clinical management of CVCs. The guidelines supply updated recommendations that may be useful in other countries as well. Literature retrieval in the Cochrane and Pubmed databases, of papers written in English or Swedish and pertaining to CVC management, was done by members of a task force of the Swedish Society of Anaesthesiology and Intensive Care Medicine. Consensus meetings were held throughout the review process to allow all parts of the guidelines to be embraced by all contributors. All of the content was carefully scored according to criteria by the Oxford Centre for Evidence-Based Medicine. We aimed at producing useful and reliable guidelines on bleeding diathesis, vascular approach, ultrasonic guidance, catheter tip positioning, prevention and management of associated trauma and infection, and specific training and follow-up. A structured patient history focused on bleeding should be taken prior to insertion of a CVC. The right internal jugular vein should primarily be chosen for insertion of a wide-bore CVC. Catheter tip positioning in the right atrium or lower

third of the superior caval vein should be verified for long-term use. Ultrasonic guidance should be used for catheterisation by the internal jugular or femoral veins and may also be used for insertion via the subclavian veins or the veins of the upper limb. The operator inserting a CVC should wear cap, mask, and sterile gown and gloves. For long-term intravenous access, tunnelled CVC or subcutaneous venous ports are preferred. Intravenous position of the catheter tip should be verified by clinical or radiological methods after insertion and before each use. Simulator-assisted training of CVC insertion should precede bedside training in patients. Units inserting and managing CVC should have quality assurance programmes for implementation and follow-up of routines, teaching, training and clinical outcome. Clinical guidelines on a wide range of relevant topics have been introduced, based on extensive literature retrieval, to facilitate effective and safe management of CVCs.

Accepted for publication 27 January 2014

© 2014 The Acta Anaesthesiologica Scandinavica Foundation.
Published by John Wiley & Sons Ltd

SUBOPTIMAL clinical use of central venous catheters (CVCs), intended for safe and reliable vascular access, may influence patient morbidity and even mortality. Current guidelines by others on various aspects of vascular access have been limited to short-term access,¹ to the prevention of infection,² or to haematological³ or renal⁴ problems.

This paper, based on extended review of the literature, reports updated national guidelines for clinical management of CVC in adults set by a task force of the Swedish Society of Anaesthesiology and

Intensive Care Medicine (SFAI) based on current scientific evidence and empirical experience regarding insertion and management of non-tunnelled CVC, tunnelled CVC with anchoring cuffs, dialysis catheters, implanted subcutaneous ports, and peripherally inserted CVCs (PICCs).

Methods

A task force was recently commissioned by the SFAI to design national guidelines for management of

CVC in Sweden based on current scientific and empirical knowledge (Table 1).

Literature retrieval, in the Cochrane and Pubmed database (Appendix 1), of papers written in English or Swedish, and pertaining to CVC management, was done by the members of the task force according to agreed individual responsibilities for specific relevant topics. After this initial screening of the literature, all articles considered relevant to key issues were objectively evaluated, while only those with the highest available evidence were subsequently included in the review.

Each subtopic was discussed during the task force meetings, and disagreements regarding evaluation of evidence and focus of the guidelines were handled by group discussions aiming at consensus.

Six consensus meetings were arranged during the 2-year working process to enable all parts of the guidelines to be embraced by all contributors. All of the content was carefully graded according to criteria by the Oxford Centre for Evidence-Based Medicine (Appendix 2). Expert opinion was considered as appropriate surrogate for low-grade scientific evidence (also indicated as evidence level 5, expert opinion).

Bleeding diathesis

Bleeding associated with CVC insertion has a reported incidence of 0.5–1.6%⁵ but is rarely fatal. In case reports, fatal outcome due to bleeding is most often considered a consequence of inadequate technique or management rather than bleeding diathesis.^{6,7}

Bleeding complications associated with CVC removal are rare^{8,9} and have not been reported to be associated with moderately decreased platelet count and/or increased prothrombin time – international normalised ratio (PT-INR) levels.¹⁰

A structured assessment of bleeding diathesis (including heredity, history of bleeding, complications associated with previous surgery, and drugs affecting coagulation) should be made before CVC insertion. Laboratory tests should then be omitted if no coagulation disorder is suspected^{11–13} (evidence level 3, recommendation grade B). Mechanical tests of bleeding time are unreliable and should not be used in this context.¹⁴

In patients with significantly abnormal coagulation tests or clinically suspected coagulation disorder, an easily compressible vessel should be chosen and the catheter inserted by an experienced operator using optimal techniques^{6,7,15} (A. Larsson,

unpublished data, 2009) (evidence level 2a, recommendation grade B). There is no scientific evidence for preferring cut-down to percutaneous techniques in patients with coagulation disorders¹⁶ (evidence level 2b, recommendation grade B).

Coagulation disorders should not be reversed routinely, e.g. by administration of fresh frozen plasma, tranexamic acid, desmopressin, vitamin K, or platelets, but pharmacological treatment may be considered in selected patients^{11,17} (evidence level 2a, recommendation grade B).

For non-tunnelled catheters, platelet count levels below 50 10⁹/l have been reported to be associated with increased risk of bleeding or haematoma formation, and catheterisations should be done by experienced operators using optimal techniques^{18,19} (evidence level 2a, recommendation grade B).

Moderately prolonged activated partial thromboplastin time (APTT) levels do not increase the risk of bleeding or haematoma formation. In our opinion, levels of up to 1.3 times the upper reference interval in the absence of other coagulation disorder do not increase the risk of bleeding and are acceptable for routine cannulation^{12,18,20–24} (evidence level 4, recommendation grade C). In contrast, moderately increased APTT levels may indicate severe coagulation disorder in patients with haemophilia (evidence level 5, expert opinion, recommendation grade D).

Levels of PT-INR at or below 1.8 have not been reported to be associated with higher risk of bleeding or haematoma formation^{11,18,19,21,23} (evidence level 3b, recommendation grade B).

Several drugs influencing haemostasis merit added vigilance. Routine procedures are adequate in patients on monotherapy with acetylsalicylic acid, non-steroidal anti-inflammatory drugs or prophylactic anticoagulants (e.g., low-dose heparin, low-molecular-weight heparin, pentasaccharides, thrombin inhibitors) (recommendation grade D). However, if these drugs are combined, in particular clopidogrel and acetylsalicylic acid, patients should be catheterised by experienced operators using the safest possible techniques²⁵ (recommendation grade D).

Patients with haemophilia are often given factor concentrate before catheterisation despite weak evidence for this practice²⁶ (evidence level 5, expert opinion, recommendation grade D).

Vascular access site

CVCs are commonly inserted via the internal jugular, external jugular, subclavian, or femoral veins. There

Table 1

Summary of the National Guidelines for Central Venous Catheterisation in Sweden, based on current international scientific and empirical knowledge, and endorsed by the Swedish Society of Anaesthesiology and Intensive Care Medicine in 2010 for safer management of central venous catheters in Scandinavia.

National Guidelines for Central Venous Catheter (CVC) Management in Sweden

Bleeding diathesis

- A structured patient history focused on bleeding should be taken prior to insertion of a central venous catheter (C).
- Patients without a history of or symptoms of a coagulation disorder do not require coagulation tests prior to insertion of a CVC (B).
- In patients with bleeding diathesis, CVC should be inserted by an experienced operator using optimal technique (B).
- Reversal of coagulation disorders may be considered but should not be done routinely (B).
- Platelet count $\geq 50 \cdot 10^9/l$, prothrombin time (PT-INR) $\leq 1,8$ or activated partial thromboplastin time (APTT) $\leq 1,3$ times the upper normal range are considered limits for routine CVC insertion in patients with no bleeding diathesis (B,C).
- Routine CVC insertion may be done despite monotherapy with acetyl salicylic acid, a non-steroid anti-inflammatory drug or a prophylactic anticoagulant (heparins, pentasaccharides, or thrombin inhibitors) (D).

Vascular access site

- The right internal jugular vein should primarily be chosen for insertion of a wide-bore CVC (≥ 10 Fr) (B).
- For long-term access, the subclavian veins and the veins of the arm should be avoided in patients requiring, or possibly requiring, haemodialysis, and in patients where ipsilateral mastectomy has been, or will be, carried out (B).
- The subclavian veins should be avoided in patients with coagulopathy (D).

Catheter tip positioning

- Catheter tip positioning in the right atrium or lower third of the superior caval vein should be verified for long-term use, haemofiltration/dialysis, central venous pressure measurement or infusion of tissue-toxic agents (e.g., chemotherapy) (C).
- Control by chest X-ray should be done with the patient supine (C).
- Pre-operative fluoroscopy may be used to guide correct catheter positioning for long-term use and post-operative chest X-ray is then required only if complications are suspected (B).

Ultrasonic guidance

- Ultrasonic guidance should be used for catheterisation by the internal jugular or femoral veins, and may also be used for insertion via the subclavian veins or the veins of the upper limb (B).

Associated infection

- Central venous catheters should be inserted and managed under sterile conditions (A).
- Pre-operative hair shortening may be done when indicated (D).
- The operator inserting a CVC should wear cap, mask, and sterile gown and gloves (A).
- Multiple lumen catheters may be used when indicated, but the number of lumens should be kept at a minimum (B).
- For long-term intravenous access, tunnelled CVC or subcutaneous venous ports are preferred (A).
- Clinical routines and the incidence of CVC-associated bacterial colonisation and infection should be monitored continuously (A).
- Catheters with antimicrobial coating, and daily total-body disinfection with chlorhexidine in intensive care patients, may be considered to reduce unacceptably high CVC-associated infection rates despite correctly implemented hygiene routines (A).
- Routine prophylactic antibiotic administration before catheterisation is not recommended (A).
- A monofilament suture should be used for fixing catheters for short-term use (C), and a sterile cotton dressing or a semipermeable polyurethane film should cover the site (A).
- The entry site should be inspected, and the patient should be evaluated for signs of infection, regularly (A).
- Sterile dressings should be changed at least every seventh day and more often if indicated (B).
- Dressings containing chlorhexidine sponges may be considered (A).
- Needleless membranes should be connected to each CVC port (C) and be appropriately disinfected before each use (A).
- Injectable membranes, connectors, and valves connected to the CVC should be changed every third day in in-hospital patients and at least weekly in outpatient care (C).
- Heparin or antibiotic locks for the purpose of reducing the rate of CVC-related infection should be considered only for long-term access in immunocompromised patients (B).
- Cultures from the blood and catheter tip should be obtained in suspected CVC-associated infection (C).
- When a culture from the catheter tip is to be obtained, the skin around the CVC should be disinfected with chlorhexidine-ethanol solution and allowed to dry before CVC extraction (D).

Associated mechanical trauma

- The decision to adjust the position of a CVC should be based on both clinical and radiological findings (C).
- A chest X-ray should be made when pneumothorax or haemothorax is suspected (C).
- Patients prone to cardiac dysrhythmia should be subjected to electrocardiogram monitoring during insertion, and neither the guidewire nor the catheter should be allowed to enter the heart (D).
- In accidental arterial catheterisation regardless of catheter dimension at a non-compressible site and also for catheters > 7 Fr regardless of site, the catheter should be secured in place and a vascular surgeon be consulted (C).
- To minimise the risk of nerve damage, multiple punctures should be minimised by using ultrasonic guidance when possible (D).
- The risk of venous air embolism is minimised by head-down patient positioning during catheter insertion and extraction, and by applying a tight dressing immediately after extraction (D).

Associated venous thrombo-embolism

- For long-term vascular access in patients undergoing haemodialysis, an arteriovenous fistula should be preferred to a CVC because of lower risks of dysfunction and associated infection and venous thrombosis (A).
- Routine use of anticoagulants to prevent CVC-associated thrombosis is not recommended (D).
- Routine treatment of asymptomatic CVC-associated thrombosis is not recommended (D).
- Anticoagulants should be given to patients with symptomatic associated deep venous thrombosis (B).
- Whether the CVC should be removed or not in a patient with symptomatic CVC-associated venous thrombosis depends on the need for continued central venous access and anticipated problems with recatheterisation (B).
- Thrombolytic therapy should only be given to patients with life-threatening-associated deep venous thrombosis (B).

Catheter dysfunction

- Intravenous position of the catheter tip should be verified by clinical or radiological methods after insertion and before each use (B).
- Central venous catheters should be flushed with saline after each use (B).
- Thrombolytic drugs may be used in thrombosis-related catheter occlusion (B).
- Ethanol, hydrochloric acid or sodium hydroxide may be injected in catheter occlusion due to sedimentation of drugs or lipids (C).
- Changing the CVC over a guidewire should be considered when the above measures have failed (B).
- Patients with previous long-term central venous access should undergo mapping of the central venous system by computerised tomography or magnetic resonance imaging before recatheterisation, and endovascular expertise should be consulted in those with verified central venous stenosis (C).

Training and follow-up

- Simulator-assisted training of CVC insertion should precede bedside training in patients (B).
 - Central venous catheterisation, with and without ultrasonic guidance, should be continuously practiced (D).
 - Units inserting and managing CVC should have quality assertion programmes for implementation and follow-up of routines, teaching, training, and clinical outcome (A).
-

Capitals in parentheses (A–D) indicate grades of clinical recommendation according to criteria set by the Oxford Centre for Evidence-Based Medicine, revised in 2009.

Table 2

Clinical aspects considered relevant for central venous catheterisation of specific veins.

Vein	Clinical aspects	
	Supporting choice of vein for vascular access	Discouraging choice of vein for vascular access
Internal jugular	Ultrasonic guidance easier External compression possible Lower risk of mechanical complications Lower risk of thrombosis or stenosis	Patient discomfort
Subclavian	Patient comfort	Ultrasonic guidance more difficult External compression difficult or even impossible Higher risk of pneumothorax/haemothorax Higher risk of thrombosis or stenosis (particularly during long-term use) Risk of pinch-off syndrome (during long-term use)
Femoral	Ultrasonic guidance easier External compression possible	Higher risk of thrombosis Patient discomfort

Individual patient- (e.g., venous thrombosis, coagulopathy, vascular anatomy) and operator- (e.g. clinical skills, experience) associated issues should also be considered.

is no unequivocal evidence, based on controlled, randomised trials, for choosing particular locations under specific clinical conditions (Table 2).

Aspects on associated mechanical trauma

Cannulation of the internal jugular veins is associated with lower incidence of pneumothorax than of the subclavian veins.²⁷ A randomised study of dialysis catheters reported similar incidences of associated infection, but more associated bleeding, in internal jugular compared with femoral cannulations²⁸ (evidence level 1b). The risk of malfunction was found to be higher in dialysis catheters inserted via the left internal jugular vein compared with the right internal jugular vein or the femoral veins²⁹ (evidence level 2b). Cannulation-induced bleeding with haematoma formation is uncommon but has been reported to have compromised the upper airway after jugular or (particularly) carotid puncture, and to be difficult to manage by external compression after subclavian puncture.³⁰

Aspects on associated infection

For short-term use, the subclavian veins have been reported to be associated with lower incidence of associated infection than the internal jugular or femoral veins.^{31,32} However, according to a recent meta-analysis, there is no difference in the incidence of catheter-associated blood-borne infection between those three sites of vascular access, probably as a result of the implementation of new procedures and techniques for prevention³³ (evidence level 1b). Furthermore, possible benefits of a lower risk of infection associated with subclavian cannulation should be weighed against a higher

risk of mechanical complications, e.g., pneumothorax or bleeding^{31,32,34-39} (evidence level 2b). In intensive care settings, the risk of CVC-associated infection seems to be similar in internal jugular and femoral cannulations²⁸ (evidence level 1b). The basilic and cephalic veins are commonly used for introduction of PICC. Their risks of cannulation-associated infection may be similar to those of the subclavian and internal jugular veins^{40,41} (evidence level 2b).

Aspects on associated thromboembolism

Dialysis catheters have been reported to be associated with higher incidence of thrombosis or stenosis in the subclavian than in the internal jugular veins^{42,43} (evidence level 2b), and the incidence is even higher in the femoral veins^{31,44} (evidence level 1b). Two studies have reported higher incidences of thrombosis after CVC insertion by the left compared with the right, internal jugular, or subclavian veins in patients with malignant disease^{45,46} (evidence level 4), but no difference between the left and right sides was found in a later prospective study⁴⁷ (evidence level 2c). The risk of thromboembolic complications for small-bore catheters, including those inserted by peripheral routes, is not well defined, but PICC inserted via arm veins have been reported to be associated with more local and central venous thrombosis.⁴¹ Because thromboses in subclavian and/or arm veins may render future establishment of arteriovenous fistulas for haemodialysis more difficult, these veins should be avoided for long-term central venous access in patients who might require future haemodialysis^{4,48,49} (evidence level 2a, recommendation grade B).

Catheter tip positioning

There are no conclusive studies on optimal catheter tip positioning.^{4,50–54} Radiographic verification of the catheter tip position is influenced by the position of the patient,^{55,56} but anatomical variation⁵⁷ (evidence level 4) and radiological landmarks may also influence radiographic interpretation of the catheter tip position^{50,57} (evidence level 2b).

With respect to the risk of complications or catheter dysfunction, optimal tip positioning of catheters inserted via jugular, subclavian, or arm veins has been suggested to be within the inferior part of the superior caval vein^{58,59} or within the right atrium⁴ (evidence level 5, expert opinion). Nevertheless, cases of perforation,^{50,60} thrombosis,^{61–64} and catheter dysfunction⁶⁵ have been reported regardless of the initial catheter position (evidence level 4).

Case reports of cardiac tamponade associated with catheter tips positioned within the right atrium⁶⁶ have led the American Federal Drug Administration to recommend right atrial tip positioning to be avoided. However, erosive perforation has almost exclusively been described for rigid catheter materials^{67,68} (evidence level 4). In clinical practice, those materials have gradually been replaced by more flexible ones, e.g., silicone or polyurethane.

Five^{69–73} out of seven^{46,69–74} non-randomised, retrospective studies in patients with known malignant disease have reported increased risk of symptomatic venous thrombosis to be associated with tip positioning peripherally to the right atrium (evidence level 4). The remaining two studies^{46,74} were inconclusive in this respect.

For intermittent haemodialysis, right atrial catheter tip positioning may be necessary to maintain high blood flow, which is also why the American National Kidney Foundation recommends the catheter tip to be placed within or close to the right atrium.^{4,52} For continuous haemodialysis, calling for lower rates of blood flow, a position in the superior caval vein is often adequate.⁷⁵

Optimal catheter tip positioning via the femoral veins has not been well elucidated, but for long-term use, the catheter tip should probably be positioned above the inferior caval entry points of the renal veins⁷⁶ (evidence level 4).

No association with vascular perforation, severe cardiac arrhythmias, local venous thrombosis, or clinical dysfunction of the central nervous system has been shown for short-term use of extrathoracically positioned catheters made of modern softer materials²⁷ (evidence level 2c).

Pre-operative fluoroscopy is useful to facilitate optimal long-term catheter tip positioning,⁷⁷ and chest X-ray is then required only when clinical complications are obvious or suspected^{78–81} (evidence level 2c).

Ultrasonic guidance

There is compelling evidence that ultrasound-guided CVC insertion via the internal jugular veins is associated with higher success rate and fewer mechanical complications compared with traditional techniques based on external anatomical landmarks^{47,82,83} (evidence level 1a, recommendation grade A). Additionally, the femoral veins are suitable for ultrasound-guided puncture^{83,84} (evidence level 2a, recommendation grade B) as are the subclavian and axillary veins^{85,86} (evidence level 2a, recommendation grade B). Ultrasonic guidance has also made the deep veins of the upper arm more available for PICC insertion, which may have reduced the complication rate, but randomised controlled studies are still lacking.

Associated infection

Prevention

Catheter-associated infection is an important cause of morbidity and mortality,^{87,88} particularly in severely ill or injured patients. The incidence varies between countries and hospitals from 0 to 30 per 1000 catheter days.^{34,89} These infections prolong individual hospital stay by 10–20 days and are estimated to correspond to 12% of all infections in intensive care patients.^{89–91} The mortality of CVC-associated infection has been estimated to be up to 25%.⁹² Available studies on mortality are more than 10 years old, and the wide range quoted may reflect differences in practice and settings. Notwithstanding, since the risk of CVC-associated infection increases over time, any CVC should be removed as soon as it is no longer required for safe individual patient care.

Continuous follow-up of clinical routines and staff awareness by designated CVC teams has been reported to reduce CVC-associated infection rates^{93–96} (evidence level 1a).

The physician inserting a CVC should wear cap, mask, sterile gown, and sterile gloves. The cannulation area should be disinfected by thorough application of a mixture of chlorhexidine and ethanol, which is then left to evaporate, and the patient should be completely covered with sterile drapes^{97–102} (evidence level 1a).

Pre-operative hair shortening, but not shaving, may be considered¹⁰³ (evidence level 2b). Large randomised controlled studies on catheter materials vs. infection risks are lacking.¹⁰⁴ Clinical use of multiple-lumen catheters is considered to increase the risk of infection¹⁰⁵ (evidence level 2b).

For more than 3–4 weeks of clinical use, a cuffed tunnelled CVC or a subcutaneous venous port (SVP) should be chosen^{90,106} (evidence level 1a).

PICCs are increasingly used for long-term access. There is no high-grade evidence to support long-term use of PICC over tunnelled CVC or SVPs regarding overall complication rates^{40,41} (evidence level 5, expert opinion).

For short-term use, antibiotic coating of non-tunnelled CVC with chlorhexidine/silversulfadiazine or minicycline/rifampicine reduces infection rates more effectively than tunnelling with conventional catheters¹⁰⁷ (evidence level 2b).

Systemic prophylactic antibiotics should not be given routinely for CVC insertion^{89,108–110} (evidence level 1a) but may be considered in patients with increased risk of infection^{111–113} (evidence level 4).

The rates of infection and colonisation with multiresistant bacteria in intensive care patients are lower during daily whole-body chlorhexidine disinfection than with soap-and-water washing^{114–117} (evidence level 2b). This measure may be considered as an adjunct to correctly implemented hygiene routines when CVC-associated infection rates remain unacceptably high (recommendation grade B).

Exchange over guidewire may be considered in catheter dysfunction or when a change of the type of catheter is indicated. This procedure is associated with lower risk of mechanical complications but with higher risk of associated infection compared with conventional insertion at a fresh site^{89,118} (evidence level 2a).

Fixation with monofilament sutures is recommended. Staples or suture-less anchoring devices may reduce the risk of local infection but increase that of accidental catheter extraction^{119–122} (evidence level 4).

Dressings should be changed with sterile techniques including use of clean or sterile gloves⁸⁹ (evidence level 1a). The skin and catheter should be disinfected with chlorhexidine-ethanol solution and left to dry¹²³ (evidence level 1a). The cannulation site should then be covered with sterile gauze or highly permeable polyurethane film^{124,125} (evidence level 2). Dressing with a chlorhexidine-

containing sponge may be effective, but there is a risk of skin rash^{126–130} (evidence level 1b). Dressings should be changed once to seven times a week depending on the setting¹³¹ (evidence level 2b). For cuffed or tunnelled CVC, dressings should be changed as described earlier until the cuff is anchored, after which they may probably be omitted⁸⁹ (evidence level 4).

Most studies report clinical use of needleless membranes to be associated with lower rates of CVC-associated infection^{132–139} (evidence level 4). Together with connectors and valves, needleless membranes should be changed every third day to prevent colonisation and infection, and even longer (4- to 7-day) intervals have been proposed to be safe^{140–143} (evidence level 2b).

The working group recommends CVCs to be consistently flushed with saline after each injection or sampling of blood (evidence level 5, expert opinion). No significant difference has been shown between flushing and instillation of heparin compared with saline regarding rates of infection or occlusion^{144–149} (evidence level 3), but immunodeficient patients may benefit from instillation of heparin.¹⁵⁰ Regular flushing of resting long-term systems is not well studied and does not seem to reduce the risk of occlusion.¹⁵¹ Antibacterial locks may reduce the incidence of CVC-associated infection, but the risk of increased bacterial resistance to antibiotics has not been elucidated¹⁵² and should be considered.

Management

Various sets of diagnostic criteria have been proposed for associated infection. The core temperature should be measured, and basic laboratory tests for analysis of blood cell count and C-reactive protein be obtained together with cultures from the catheter tip, insertion site, and blood^{106,153} (evidence level 2c-4). Blood cultures should be taken from all CVC lumens and a peripheral vein simultaneously, and should be evaluated including differential time to positivity.¹⁵⁴ Before a CVC is removed, if a culture from the tip is planned, the skin around the cannulation site should be disinfected with chlorhexidine-ethanol solution and left to dry.¹⁵⁵

Empirical antibiotic therapy should cover Gram-positive (including coagulase-negative staphylococci) and Gram-negative pathogens before narrowing the antibiotic spectrum in response to microbiology reports. Antimycotic drugs should be added in patients with critical illness, neutropenia, or parenteral nutrition. See also Figs 1–2.

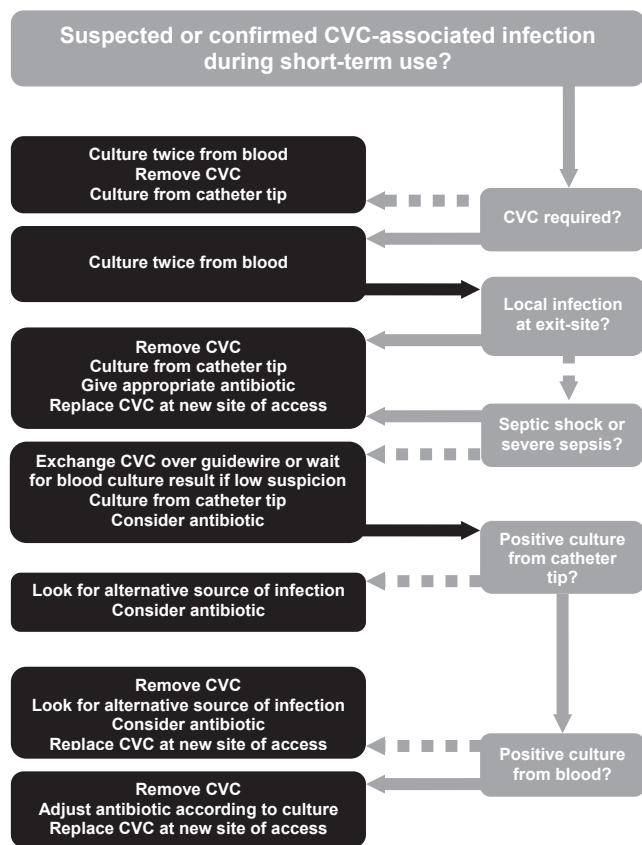


Fig. 1. Proposed clinical management of infections associated with short-term use of central venous catheters (CVCs).

Associated mechanical trauma

During the cannulation procedure and before subsequent clinical use of the CVC, appropriate catheter position should be verified by aspiration of venous blood, by backflow into an intravenous fluid bag, or, in case of ambiguity, by chest X-ray with infusion of contrast via the catheter^{27,156–158} (evidence level 2b). During insertion, the catheter tip position may also be adjusted according to electrocardiogram¹⁵⁹ or central venous pressure patterns¹⁶⁰ (evidence level 5, expert opinion).

The incidences of pneumothorax after CVC insertion via the internal jugular and subclavian veins are 0.3–1.0% and 1.6–2.3%, respectively.^{158,161} Patients with pneumothorax requiring pleural drainage may show dyspnoea, tachypnoea, cough, or peripheral oxygen saturation < 90% at an early stage,¹⁵⁸ whereas a pneumothorax corresponding to approximately 30% or less of the pleural cavity is associated with few clinical signs and usually requires no drainage.^{158,162}

A normal chest X-ray immediately after catheterisation does not exclude pneumothorax, which may

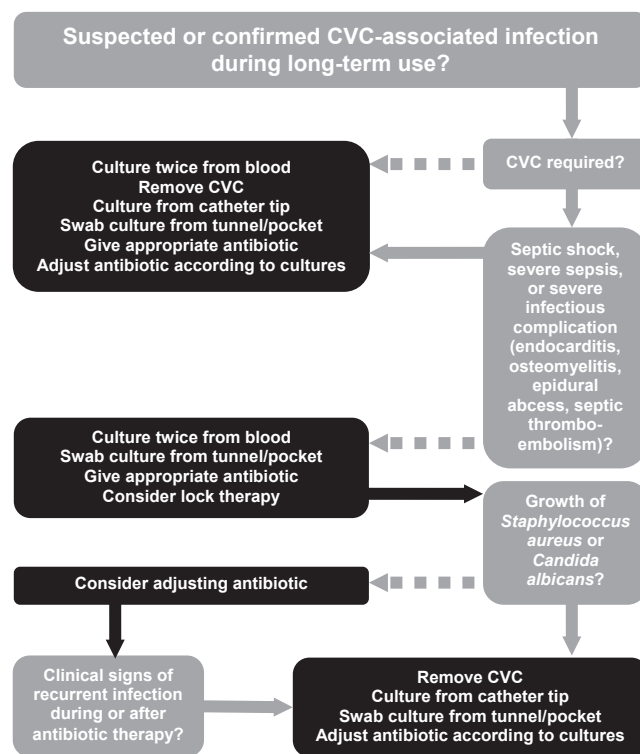


Fig. 2. Proposed clinical management of infections associated with long-term use of central venous catheters (CVCs).

develop insidiously.^{163–165} Radiographic control is recommended if pneumothorax is suspected during catheterisation or if the patient has onset of respiratory symptoms, or is hypoxic, after the cannulation procedure (evidence level 4, recommendation grade C).

Traumatic injury to catheters or vessels during insertion or clinical use may cause subcutaneous spread of intravenous fluid to form local tissue oedema.¹⁶⁶ Extravasation of intravenously infused fluid may also lead to hydrothorax¹⁶⁷ or, if the perforation is located within the pericardial folds,¹⁶⁸ to cardiac tamponade with high mortality.¹⁶⁹ Vascular perforation has been reported to be more common in left-sided approaches possibly because of the more acute angle between the guidewire and catheter, and the superior caval wall,^{59,170} but damage to the vein from catheter erosion is less common with modern pliant catheter materials.^{67,68}

Benign cardiac dysrhythmia resulting from a guidewire or catheter tip in the atrium or the ventricle, particularly during the cannulation procedure, is usually transient^{171,172} (evidence level 3b). However, severe arrhythmias have been reported during catheter insertion^{173–175} or use^{173–175} (evidence level 4).

The incidence of accidental arterial puncture is approximately 6%,¹⁷⁶ while arterial catheterisation has been reported in 0.1–1.0% of CVC insertion procedures.¹⁷⁷ Serious complications, such as haematoma, pseudo-aneurysm with or without neural compression, arterial thrombosis or dissection, stroke, arteriovenous fistula, haemothorax, haemomediastinum, or cardiac tamponade, may occur.^{30,178–184} Systematic efforts directed at their prevention by adopting safe ultrasound-guided techniques are mandatory.

Case series indicate that an arterial catheter of 7 Fr or less, accidentally inserted at a compressible site, may be safely extracted followed by external compression for 10 min.³⁰ In contrast, a vascular surgeon should be consulted for safe removal of any arterial catheter larger than 7 Fr or placed at a non-compressible site. A closure device, with endovascular or open techniques, may be used^{30,180} (evidence level 4).

Local neural damage associated with catheter insertion may result from mechanical trauma, neural compression by haematoma, or extravasation of cytotoxic drugs. Neurological clinical signs are usually transient, but occasionally, the damage may induce permanent sequelae.¹⁸⁵

Venous air embolism may be associated with CVC insertion, CVC extraction, or exchange of infusion tubing.^{186,187} The mortality rate in massive air embolism is high,¹⁸⁸ but massive embolisation associated with catheter insertion or extraction is likely to be prevented by a head-down patient position (particularly during introduction over guidewire) and by an air-tight dressing after extraction¹⁸⁸ (evidence level 5, expert opinion).

Catheters inadvertently directed cranially in the internal jugular vein are often removed or redirected to avoid local thrombosis or retrograde injection into the cerebral circulation.¹⁸⁹ The latter is however unlikely due to the high venous flow in this vessel, and a cranially directed CVC for short-term use may thus be left in place⁶³ (evidence level 5, expert opinion).

Associated venous thromboembolism

Heparin may decrease the risk of associated venous thromboembolism,^{190–193} but because it also considerably increases the risk of bleeding, prophylactic heparin cannot be recommended in patients with CVC (evidence level 1a, recommendation grade A). Nor is routine anticoagulant therapy indicated in patients with asymptomatic venous thrombosis

(recommendation grade D). The use of prophylactic anticoagulants in catheterised patients with known inborn hypercoagulability has not been studied.¹⁹⁴

No randomised studies on the treatment of symptomatic associated venous thrombosis have been published. However, several cohort studies have shown safe and successful treatment of deep venous thromboses in the upper extremities with regimens similar to those recommended for venous thromboses in the lower extremities^{195–197} (evidence level 4). Optimal durations of treatment vary considerably, depending on individual clinical factors, and have not been well elucidated^{198–201} (evidence level 4).

Catheter dysfunction

Catheter occlusion may result from intraluminal or extraluminal thrombosis, deposition of residues of lipids, precipitation (e.g., of calcium phosphate) by simultaneous infusion of solutions with low and high pH, angulation or folding of the catheter, pinch-off syndrome (compression of the catheter between the clavicle and first rib, mainly during long-term use), or intramural migration of the catheter tip.

The aetiology should be sought by considering how the catheter has been used before the occlusion¹⁹⁹ (evidence level 2b). Occlusion induced by intraluminal thrombosis or non-symptomatic venous thrombosis may be treated with systemic or local administration of thrombolytic drugs^{199,202} (evidence level 2b, recommendation grade B). In catheters blocked by fibrin sheath or thrombosis, a stripping procedure may be considered if thrombolytic therapy fails^{49,203} (evidence level 4). Asymptomatic fibrin sheath and/or thrombosis formation around the catheter tip is common but has little clinical implication for short-term use.^{204–209}

Ethanol or sodium hydroxide may be instilled to remove lipid deposits, but it should be considered that ethanol may damage polyurethane catheters^{210,211} (evidence level 4, recommendation grade C). Intraluminal deposits from acid solutions, e.g., of calcium phosphate, may be cleared by careful local instillation of hydrochloric acid²¹² and those from alkaline solutions by instillation of sodium hydroxide or bicarbonate.²¹¹ Catheter exchange over a guidewire may be considered for any type of occlusion.¹⁹⁹

In patients with renal failure in need of long-term vascular access for haemodialysis and parenteral

nutrition, central dialysis catheters should not be the first choice because of increased risk of thrombosis and infectious complications^{213,214} (evidence level 2c, recommendation grade B). Accordingly, PICC should not be chosen in patients with potential future need of a brachial arteriovenous fistula for haemodialysis²¹⁵ (evidence level 2c, recommendation grade B).

The incidence of associated venous stenosis increases with the number of catheters, the total duration of CVC use, and associated infections or thrombosis.^{216–218} For patients with those risk factors and for patients with a verified central venous stenosis, mapping of the central venous system by computerised tomography or magnetic resonance tomography scanning should be considered, and endovascular expertise be consulted before de novo CVC insertion^{214,219} (evidence level 4, recommendation grade C).

Training and follow-up

Several manikins or dummies for simulation training of central venous cannulation, with or without ultrasonic guidance, are available.²²⁰ Such training should precede bedside practice^{220–228} (evidence level 2a, recommendation grade B).

Continuous training of all clinically active CVC operators, regardless of level of experience, has been reported to reduce the risk of complications (recommendation grade D).^{229–231}

All health-care units involved in CVC insertion and use should have quality assertion programmes for implementation and follow-up of routines, teaching, training, and clinical outcome (recommendation grade A).⁹³

Concluding remarks

Based on extensive literature retrieval, thousands of scientific papers on central venous catheterisation have been systematically reviewed by a Swedish task force, commissioned by the Swedish Society of Anaesthesiology and Intensive Care Medicine, to produce relevant, useful, and reliable national CVC guidelines. Endorsed by the Swedish Society in 2010 to facilitate safer management of CVC in Scandinavia, these guidelines are considered to cover a wide range of key topics, including bleeding diathesis, vascular approach, ultrasonic guidance, catheter positioning, prevention and management of mechanical trauma or infection, and specific training and follow-up.

Acknowledgement

We thank the board of the SFAI for having initiated and enabled this task force.

Conflicts of interest: None of the authors declare any conflicts of interest.

Funding: SFAI covered travel expenses for the consensus meetings.

References

1. Rupp SM, Apfelbaum JL, Blitt C, Caplan RA, Connis RT, Domino KB, Fleisher LA, Grant S, Mark JB, Morray JP, Nickinovich DG, Tung A. Practice guidelines for central venous access: a report by the American Society of Anesthesiologists Task Force on Central Venous Access. *Anesthesiology* 2012; 116: 539–73.
2. O'Grady NP, Alexander M, Burns LA, Dellinger EP, Garland J, Heard SO, Lipsett PA, Masur H, Mermel LA, Pearson ML, Raad II, Randolph AG, Rupp ME, Saint S. Guidelines for the prevention of intravascular catheter-related infections. *Am J Infect Control* 2011; 39: S1–34.
3. Bishop L, Dougherty L, Bodenham A, Mansi J, Crowe P, Kibbler C, Shannon M, Treleaven J. Guidelines on the insertion and management of central venous access devices in adults. *Int J Lab Hematol* 2007; 29: 261–78.
4. Brouwer D, Bunchman TE, Dinwiddie LC, Goldstein SL, Henry ML, Konner K, Lumsden A, Vesely TM. Clinical practice guidelines for vascular access. *Am J Kidney Dis* 2006; 48: S176–247.
5. Eisen LA, Narasimhan M, Berger JS, Mayo PH, Rosen MJ, Schneider RF. Mechanical complications of central venous catheters. *J Intensive Care Med* 2006; 21: 40–6.
6. Domino KB, Bowdle TA, Posner KL, Spittellie PH, Lee LA, Cheney FW. Injuries and liability related to central vascular catheters: a closed claims analysis. *Anesthesiology* 2004; 100: 1411–8.
7. Hove LD, Steinmetz J, Christoffersen JK, Moller A, Nielsen J, Schmidt H. Analysis of deaths related to anesthesia in the period 1996–2004 from closed claims registered by the Danish Patient Insurance Association. *Anesthesiology* 2007; 106: 675–80.
8. Collini A, Nepi S, Ruggieri G, Carmellini M. Massive hemothorax after removal of subclavian vein catheter: a very unusual complication. *Crit Care Med* 2002; 30: 697–8.
9. Lee AC. Elective removal of cuffed central venous catheters in children. *Support Care Cancer* 2007; 15: 897–901.
10. Stecker MS, Johnson MS, Ying J, McLennan G, Agarwal DM, Namyslowski J, Ahmad I, Shah H, Butty S, Casciani T. Time to hemostasis after traction removal of tunneled cuffed central venous catheters. *J Vasc Interv Radiol* 2007; 18: 1232–9, quiz 40.
11. Segal JB, Dzik WH. Paucity of studies to support that abnormal coagulation test results predict bleeding in the setting of invasive procedures: an evidence-based review. *Transfusion* 2005; 45: 1413–25.
12. Dzik WH. Predicting hemorrhage using preoperative coagulation screening assays. *Curr Hematol Rep* 2004; 3: 324–30.
13. Chee YL, Crawford JC, Watson HG, Greaves M. Guidelines on the assessment of bleeding risk prior to surgery or invasive procedures. *British Committee for Standards in Haematology. Br J Haematol* 2008; 140: 496–504.
14. Radulovic V, Svensson P, Hillarp A, Berntorp E. Bleeding time determination is out of date. A non-reliable method which should not be used in routine care. *Lakartidningen* 2008; 105: 1278–83.

15. McGee DC, Gould MK. Preventing complications of central venous catheterization. *N Engl J Med* 2003; 348: 1123–33.
16. Chen PT, Sung CS, Wang CC, Chan KH, Chang WK, Hsu WH. Experience of anesthesiologists with percutaneous nonangiographic venous access. *J Clin Anesth* 2007; 19: 609–15.
17. Haas B, Chittams JL, Trerotola SO. Large-bore tunneled central venous catheter insertion in patients with coagulopathy. *J Vasc Interv Radiol* 2010; 21: 212–7.
18. Mumtaz H, Williams V, Hauer-Jensen M, Rowe M, Henry-Tillman RS, Heaton K, Mancino AT, Muldoon RL, Klimberg VS, Broadwater JR, Westbrook KC, Lang NP. Central venous catheter placement in patients with disorders of hemostasis. *Am J Surg* 2000; 180: 503–5, discussion 06.
19. Fisher NC, Mutimer DJ. Central venous cannulation in patients with liver disease and coagulopathy – a prospective audit. *Intensive Care Med* 1999; 25: 481–5.
20. DeLoughery TG, Liebler JM, Simonds V, Goodnight SH. Invasive line placement in critically ill patients: do hemostatic defects matter? *Transfusion* 1996; 36: 827–31.
21. Doerfler ME, Kaufman B, Goldenberg AS. Central venous catheter placement in patients with disorders of hemostasis. *Chest* 1996; 110: 185–8.
22. Tercan F, Ozkan U, Oguzkurt L. US-guided placement of central vein catheters in patients with disorders of hemostasis. *Eur J Radiol* 2008; 65: 253–6.
23. Foster PF, Moore LR, Sankary HN, Hart ME, Ashmann MK, Williams JW. Central venous catheterization in patients with coagulopathy. *Arch Surg* 1992; 127: 273–5.
24. Petersen GA. Does systemic anticoagulation increase the risk of internal jugular vein cannulation? *Anesthesiology* 1991; 75: 1124.
25. Di Minno MN, Prisco D, Ruocco AL, Mastronardi P, Massa S, Di Minno G. Perioperative handling of patients on antiplatelet therapy with need for surgery. *Intern Emerg Med* 2009; 4: 279–88.
26. Neunert CE, Miller KL, Journeycake JM, Buchanan GR. Implantable central venous access device procedures in haemophilia patients without an inhibitor: systematic review of the literature and institutional experience. *Haemophilia* 2008; 14: 260–70.
27. Pikwer A, Baath L, Davidson B, Perstoft I, Akeson J. The incidence and risk of central venous catheter malpositioning: a prospective cohort study in 1619 patients. *Anaesth Intensive Care* 2008; 36: 30–7.
28. Parienti JJ, Thirion M, Megarbane B, Souweine B, Ouchikhe A, Polito A, Forel JM, Marque S, Misset B, Airapetian N, Daurel C, Mira JP, Ramakers M, du Cheyron D, Le Coutour X, Daubin C, Charbonneau P. Femoral vs jugular venous catheterization and risk of nosocomial events in adults requiring acute renal replacement therapy: a randomized controlled trial. *JAMA* 2008; 299: 2413–22.
29. Parienti JJ, Megarbane B, Fischer MO, Lautrette A, Gazui N, Marin N, Hanouz JL, Ramakers M, Daubin C, Mira JP, Charbonneau P, du Cheyron D. Catheter dysfunction and dialysis performance according to vascular access among 736 critically ill adults requiring renal replacement therapy: a randomized controlled study. *Crit Care Med* 2010; 38: 1118–25.
30. Pikwer A, Acosta S, Kolbel T, Malina M, Sonesson B, Akeson J. Management of inadvertent arterial catheterisation associated with central venous access procedures. *Eur J Vasc Endovasc Surg* 2009; 38: 707–14.
31. Hamilton HC, Foxcroft DR. Central venous access sites for the prevention of venous thrombosis, stenosis and infection in patients requiring long-term intravenous therapy. *Cochrane Database Syst Rev* 2007; CD004084.
32. Richet H, Hubert B, Nitemberg G, Andreumont A, Buu-Hoi A, Ourbak P, Galicier C, Veron M, Boisvion A, Bouvier AM, et al. Prospective multicenter study of vascular-catheter-related complications and risk factors for positive central-catheter cultures in intensive care unit patients. *J Clin Microbiol* 1990; 28: 2520–5.
33. Marik PE, Flemmer M, Harrison W. The risk of catheter-related bloodstream infection with femoral venous catheters as compared to subclavian and internal jugular venous catheters: a systematic review of the literature and meta-analysis. *Crit Care Med* 2012; 40: 2479–85.
34. Hammarskjold F, Wallen G, Malmvall BE. Central venous catheter infections at a county hospital in Sweden: a prospective analysis of colonization, incidence of infection and risk factors. *Acta Anaesthesiol Scand* 2006; 50: 451–60.
35. Deshpande KS, Hatem C, Ulrich HL, Currie BP, Aldrich TK, Bryan-Brown CW, Kvetan V. The incidence of infectious complications of central venous catheters at the subclavian, internal jugular, and femoral sites in an intensive care unit population. *Crit Care Med* 2005; 33: 13–20, discussion 234–5.
36. Ruesch S, Walder B, Tramer MR. Complications of central venous catheters: internal jugular versus subclavian access – a systematic review. *Crit Care Med* 2002; 30: 454–60.
37. McKinley S, Mackenzie A, Finfer S, Ward R, Penfold J. Incidence and predictors of central venous catheter related infection in intensive care patients. *Anaesth Intensive Care* 1999; 27: 164–9.
38. Gowardman JR, Montgomery C, Thirlwell S, Shewan J, Idema A, Larsen PD, Havill JH. Central venous catheter-related bloodstream infections: an analysis of incidence and risk factors in a cohort of 400 patients. *Intensive Care Med* 1998; 24: 1034–9.
39. Moro ML, Vigano EF, Cozzi Lepri A. Risk factors for central venous catheter-related infections in surgical and intensive care units. The Central Venous Catheter-Related Infections Study Group. *Infect Control Hosp Epidemiol* 1994; 15: 253–64.
40. Hammarskjold F, Nielsen N, Rodjer S, Parsson H, Falkmer U, Malmvall BE. Peripherally inserted central venous catheter still not evaluated for clinical use. More scientific support is needed according to a literature study. *Lakartidningen* 2008; 105: 1576–80.
41. Pikwer A, Akeson J, Lindgren S. Complications associated with peripheral or central routes for central venous cannulation. *Anaesthesia* 2012; 67: 65–71.
42. Schillinger F, Schillinger D, Montagnac R, Milcent T. Post catheterisation vein stenosis in haemodialysis: comparative angiographic study of 50 subclavian and 50 internal jugular accesses. *Nephrol Dial Transplant* 1991; 6: 722–4.
43. Cimochowski GE, Worley E, Rutherford WE, Sartain J, Blondin J, Harter H. Superiority of the internal jugular over the subclavian access for temporary dialysis. *Nephron* 1990; 54: 154–61.
44. Merrer J, De Jonghe B, Golliot F, Lefrant JY, Raffy B, Barre E, Rigaud JP, Casciani D, Misset B, Bosquet C, Outin H, Brun-Buisson C, Nitenberg G. Complications of femoral and subclavian venous catheterization in critically ill patients: a randomized controlled trial. *JAMA* 2001; 286: 700–7.
45. Puel V, Caudry M, Le Metayer P, Baste JC, Midy D, Marsault C, Demeaux H, Maire JP. Superior vena cava thrombosis related to catheter malposition in cancer chemotherapy given through implanted ports. *Cancer* 1993; 72: 2248–52.

46. Craft PS, May J, Dorigo A, Hoy C, Plant A. Hickman catheters: left-sided insertion, male gender, and obesity are associated with an increased risk of complications. *Aust N Z J Med* 1996; 26: 33–9.
47. Cavanna L, Civardi G, Vallisa D, Di Nunzio C, Cappucciati L, Berte R, Cordani MR, Lazzaro A, Cremona G, Biasini C, Muroni M, Mordenti P, Gorgni S, Zaffignani E, Ambroggi M, Bidin L, Palladino MA, Rodino C, Tibaldi L. Ultrasound-guided central venous catheterization in cancer patients improves the success rate of cannulation and reduces mechanical complications: a prospective observational study of 1978 consecutive catheterizations. *World J Surg Oncol* 2010; 8: 91.
48. Trerotola SO, Kuhn-Fulton J, Johnson MS, Shah H, Ambrosius WT, Kneebone PH. Tunneled infusion catheters: increased incidence of symptomatic venous thrombosis after subclavian versus internal jugular venous access. *Radiology* 2000; 217: 89–93.
49. Knutstad K, Hager B, Hauser M. Radiologic diagnosis and management of complications related to central venous access. *Acta Radiol* 2003; 44: 508–16.
50. Rutherford JS, Merry AF, Occlshaw CJ. Depth of central venous catheterization: an audit of practice in a cardiac surgical unit. *Anaesth Intensive Care* 1994; 22: 267–71.
51. FDA Task Force. Precautions necessary with central venous catheters. *FDA Drug Bull* 1989; 15–6.
52. Clinical practice guidelines for vascular access. *Am J Kidney Dis* 2006; 48: S248–73.
53. Silberzweig JE, Sacks D, Khorsandi AS, Bakal CW. Reporting standards for central venous access. *J Vasc Interv Radiol* 2003; 14: S443–52.
54. Lewis CA, Allen TE, Burke DR, Cardella JF, Citron SJ, Cole PE, Drooz AT, Drucker EA, Haskal ZJ, Martin LG, Van Moore A, Neithamer CD, Oglevie SB, Rholl KS, Roberts AC, Sacks D, Sanchez O, Venbrux A, Bakal CW. Quality improvement guidelines for central venous access. *J Vasc Interv Radiol* 2003; 14: S231–5.
55. Nazarian GK, Bjarnason H, Dietz CA Jr., Bernadas CA, Hunter DW. Changes in tunneled catheter tip position when a patient is upright. *J Vasc Interv Radiol* 1997; 8: 437–41.
56. Kowalski CM, Kaufman JA, Rivitz SM, Geller SC, Waltman AC. Migration of central venous catheters: implications for initial catheter tip positioning. *J Vasc Interv Radiol* 1997; 8: 443–7.
57. Aslamy Z, Dewald CL, Heffner JE. MRI of central venous anatomy: implications for central venous catheter insertion. *Chest* 1998; 114: 820–6.
58. Yoffa D. Supraclavicular subclavian venepuncture and catheterisation. *Lancet* 1965; 2: 614–7.
59. Brandt RL, Foley WJ, Fink GH, Regan WJ. Mechanism of perforation of the heart with production of hydropericidium by a venous catheter and its prevention. *Am J Surg* 1970; 119: 311–6.
60. Thomas CS Jr., Carter JW, Lowder SC. Pericardial tamponade from central venous catheters. *Arch Surg* 1969; 98: 217–8.
61. Gilon D, Schechter D, Rein AJ, Gimmon Z, Or R, Rozenman Y, Slavin S, Gotsman MS, Nagler A. Right atrial thrombi are related to indwelling central venous catheter position: insights into time course and possible mechanism of formation. *Am Heart J* 1998; 135: 457–62.
62. Ghani MK, Boccalandro F, Denktas AE, Barasch E. Right atrial thrombus formation associated with central venous catheters utilization in hemodialysis patients. *Intensive Care Med* 2003; 29: 1829–32.
63. Engstrom M, Ramgren B, Romner B, Reinstrup P. Should central venous catheters, with the tip accidentally placed retrograde in the internal jugular vein, be corrected. *Acta Anaesthesiol Scand* 2001; 45: 653–4.
64. Ahmed N. Thrombosis after central venous cannulation. *Med J Aust* 1976; 1: 217–20.
65. Petersen J, Delaney JH, Brakstad MT, Rowbotham RK, Bagley CM Jr. Silicone venous access devices positioned with their tips high in the superior vena cava are more likely to malfunction. *Am J Surg* 1999; 178: 38–41.
66. Collier PE, Goodman GB. Cardiac tamponade caused by central venous catheter perforation of the heart: a preventable complication. *J Am Coll Surg* 1995; 181: 459–63.
67. Albrecht K, Nave H, Breitmeier D, Panning B, Troger HD. Applied anatomy of the superior vena cava-the carina as a landmark to guide central venous catheter placement. *Br J Anaesth* 2004; 92: 75–7.
68. Mukau L, Talamini MA, Sitzmann JV. Risk factors for central venous catheter-related vascular erosions. *JPEN J Parenter Enteral Nutr* 1991; 15: 513–6.
69. Eastridge BJ, Lefor AT. Complications of indwelling venous access devices in cancer patients. *J Clin Oncol* 1995; 13: 233–8.
70. Cadman A, Lawrance JA, Fitzsimmons L, Spencer-Shaw A, Swindell R. To clot or not to clot? That is the question in central venous catheters. *Clin Radiol* 2004; 59: 349–55.
71. Luciani A, Clement O, Halimi P, Goudot D, Portier F, Bassot V, Luciani JA, Avan P, Fria G, Bonfils P. Catheter-related upper extremity deep venous thrombosis in cancer patients: a prospective study based on Doppler US. *Radiology* 2001; 220: 655–60.
72. Caers J, Fontaine C, Vinh-Hung V, De Mey J, Ponnet G, Oost C, Lamote J, De Greve J, Van Camp B, Lacor P. Catheter tip position as a risk factor for thrombosis associated with the use of subcutaneous infusion ports. *Support Care Cancer* 2005; 13: 325–31.
73. Tesselaar ME, Ouwkerk J, Nooy MA, Rosendaal FR, Osanto S. Risk factors for catheter-related thrombosis in cancer patients. *Eur J Cancer* 2004; 40: 2253–9.
74. Morazin F, Kriegel I, Asselain B, Falcou MC. Symptomatic thrombosis in central venous catheter in oncology: a predictive score? *Rev Med Interne* 2005; 26: 273–9.
75. Moist LM, Hemmelgarn BR, Lok CE. Relationship between blood flow in central venous catheters and hemodialysis adequacy. *Clin J Am Soc Nephrol* 2006; 1: 965–71.
76. Grant JP. Anatomy and physiology of venous system vascular access: implications. *JPEN J Parenter Enteral Nutr* 2006; 30: S7–12.
77. Yevzlin AS, Song GU, Sanchez RJ, Becker YT. Fluoroscopically guided vs modified traditional placement of tunneled hemodialysis catheters: clinical outcomes and cost analysis. *J Vasc Access* 2007; 8: 245–51.
78. Keckler SJ, Spilde TL, Ho B, Tsao K, Ostlie DJ, Holcomb GW 3rd, St Peter SD. Chest radiograph after central line placement under fluoroscopy: utility or futility? *J Pediatr Surg* 2008; 43: 854–6.
79. Chang TC, Funaki B, Szymski GX. Are routine chest radiographs necessary after image-guided placement of internal jugular central venous access devices? *AJR Am J Roentgenol* 1998; 170: 335–7.
80. Brown JR, Slomski C, Saxe AW. Is routine postoperative chest X-ray necessary after fluoroscopic-guided subclavian central venous port placement? *J Am Coll Surg* 2009; 208: 517–9.
81. Caridi JG, West JH, Stavropoulos SW, Hawkins IF Jr. Internal jugular and upper extremity central venous access in interventional radiology: is a postprocedure chest radiograph necessary? *AJR Am J Roentgenol* 2000; 174: 363–6.

82. Peris A, Zagli G, Bonizzoli M, Cianchi G, Ciapetti M, Spina R, Anichini V, Lapi F, Batacchi S. Implantation of 3951 long-term central venous catheters: performances, risk analysis, and patient comfort after ultrasound-guidance introduction. *Anesth Analg* 2010; 111: 1194–201.
83. Hind D, Calvert N, McWilliams R, Davidson A, Paisley S, Beverley C, Thomas S. Ultrasonic locating devices for central venous cannulation: meta-analysis. *BMJ* 2003; 327: 361.
84. Calvert N, Hind D, McWilliams R, Davidson A, Beverley CA, Thomas SM. Ultrasound for central venous cannulation: economic evaluation of cost-effectiveness. *Anaesthesia* 2004; 59: 1116–20.
85. Muralikrishna T, Koshy T, Misra S, Sinha PK. A novel technique for easy identification of the subclavian vein during ultrasound-guided cannulation. *J Cardiothorac Vasc Anesth* 2010; 24: 210–1.
86. Fragou M, Gravvanis A, Dimitriou V, Papalois A, Kouraklis G, Karabinis A, Saranteas T, Poularas J, Papanikolaou J, Davlouros P, Labropoulos N, Karakitsos D. Real-time ultrasound-guided subclavian vein cannulation versus the landmark method in critical care patients: a prospective randomized study. *Crit Care Med* 2011; 39: 1607–12.
87. Fraenkel DJ, Rickard C, Lipman J. Can we achieve consensus on central venous catheter-related infections? *Anaesth Intensive Care* 2000; 28: 475–90.
88. Farr BM. Preventing vascular catheter-related infections: current controversies. *Clin Infect Dis* 2001; 33: 1733–8.
89. O'Grady NP, Alexander M, Dellinger EP, Gerberding JL, Heard SO, Maki DG, Masur H, McCormick RD, Mermel LA, Pearson ML, Raad II, Randolph A, Weinstein RA. Guidelines for the prevention of intravascular catheter-related infections. Centers for Disease Control and Prevention. *MMWR Recomm Rep* 2002; 51: 1–29.
90. Maki DG, Kluger DM, Crnich CJ. The risk of bloodstream infection in adults with different intravascular devices: a systematic review of 200 published prospective studies. *Mayo Clin Proc* 2006; 81: 1159–71.
91. Vincent JL, Bihari DJ, Suter PM, Bruining HA, White J, Nicolas-Chanoin MH, Wolff M, Spencer RC, Hemmer M. The prevalence of nosocomial infection in intensive care units in Europe. Results of the European Prevalence of Infection in Intensive Care (EPIC) Study. EPIC International Advisory Committee. *JAMA* 1995; 274: 639–44.
92. Polderman KH, Girbes AR. Central venous catheter use. Part 2: infectious complications. *Intensive Care Med* 2002; 28: 18–28.
93. Pronovost P. Interventions to decrease catheter-related bloodstream infections in the ICU: the Keystone Intensive Care Unit Project. *Am J Infect Control* 2008; 36: S171.e1–5.
94. Warren DK, Yokoe DS, Climo MW, Herwaldt LA, Noskin GA, Zuccotti G, Tokars JJ, Perl TM, Fraser VJ. Preventing catheter-associated bloodstream infections: a survey of policies for insertion and care of central venous catheters from hospitals in the prevention epicenter program. *Infect Control Hosp Epidemiol* 2006; 27: 8–13.
95. Warren DK, Zack JE, Mayfield JL, Chen A, Prentice D, Fraser VJ, Kollef MH. The effect of an education program on the incidence of central venous catheter-associated bloodstream infection in a medical ICU. *Chest* 2004; 126: 1612–8.
96. Faubion WC, Wesley JR, Khalidi N, Silva J. Total parenteral nutrition catheter sepsis: impact of the team approach. *JPN J Parenter Enteral Nutr* 1986; 10: 642–5.
97. Mimoz O, Villeminey S, Ragot S, Dahyot-Fizelier C, Laksiri L, Petitpas F, Debaene B. Chlorhexidine-based antiseptic solution vs alcohol-based povidone-iodine for central venous catheter care. *Arch Intern Med* 2007; 167: 2066–72.
98. Langgartner J, Linde HJ, Lehn N, Reng M, Scholmerich J, Gluck T. Combined skin disinfection with chlorhexidine/propranol and aqueous povidone-iodine reduces bacterial colonisation of central venous catheters. *Intensive Care Med* 2004; 30: 1081–8.
99. Chaiyakunapruk N, Veenstra DL, Lipsky BA, Saint S. Chlorhexidine compared with povidone-iodine solution for vascular catheter-site care: a meta-analysis. *Ann Intern Med* 2002; 136: 792–801.
100. Mimoz O, Pieroni L, Lawrence C, Edouard A, Costa Y, Samii K, Brun-Buisson C. Prospective, randomized trial of two antiseptic solutions for prevention of central venous or arterial catheter colonization and infection in intensive care unit patients. *Crit Care Med* 1996; 24: 1818–23.
101. Raad II, Hohn DC, Gilbreath BJ, Suleiman N, Hill LA, Bruso PA, Marts K, Mansfield PF, Bodey GP. Prevention of central venous catheter-related infections by using maximal sterile barrier precautions during insertion. *Infect Control Hosp Epidemiol* 1994; 15: 231–8.
102. Maki DG. Yes, Virginia, aseptic technique is very important: maximal barrier precautions during insertion reduce the risk of central venous catheter-related bacteremia. *Infect Control Hosp Epidemiol* 1994; 15: 227–30.
103. Tanner J, Moncaster K, Woodings D. Preoperative hair removal: a systematic review. *J Perioper Pract* 2007; 17: 118–21, 24–32.
104. Bouza E, Guembe M, Munoz P. Selection of the vascular catheter: can it minimise the risk of infection? *Int J Antimicrob Agents* 2010; 36 (Suppl. 2): S22–5.
105. Zurcher M, Tramer MR, Walder B. Colonization and bloodstream infection with single- versus multi-lumen central venous catheters: a quantitative systematic review. *Anesth Analg* 2004; 99: 177–82.
106. O'Grady NP, Alexander M, Dellinger EP, Gerberding JL, Heard SO, Maki DG, Masur H, McCormick RD, Mermel LA, Pearson ML, Raad II, Randolph A, Weinstein RA. Guidelines for the prevention of intravascular catheter-related infections. *Infect Control Hosp Epidemiol* 2002; 23: 759–69.
107. Casey AL, Mermel LA, Nightingale P, Elliott TS. Antimicrobial central venous catheters in adults: a systematic review and meta-analysis. *Lancet Infect Dis* 2008; 8: 763–76.
108. van de Wetering MD, van Woensel JB. Prophylactic antibiotics for preventing early central venous catheter Gram positive infections in oncology patients. *Cochrane Database Syst Rev* 2007; CD003295.
109. Karanlik H, Kurul S, Saip P, Unal ES, Sen F, Disci R, Topuz E. The role of antibiotic prophylaxis in totally implantable venous access device placement: results of a single-center prospective randomized trial. *Am J Surg* 2011; 202: 10–5.
110. Covey AM, Toro-Pape FW, Thornton RH, Son C, Erinjeri J, Sofocleous CT, Brody LA, Brown KT, Septkowitz KA, Getrajdman GI. Totally implantable venous access device placement by interventional radiologists: are prophylactic antibiotics necessary? *J Vasc Interv Radiol* 2012; 23: 358–62.
111. Howell PB, Walters PE, Donowitz GR, Farr BM. Risk factors for infection of adult patients with cancer who have tunneled central venous catheters. *Cancer* 1995; 75: 1367–75.
112. Keung YK, Watkins K, Chen SC, Groshen S, Levine AM, Douer D. Increased incidence of central venous catheter-related infections in bone marrow transplant patients. *Am J Clin Oncol* 1995; 18: 469–74.
113. Rotstein C, Brock L, Roberts RS. The incidence of first Hickman catheter-related infection and predictors of cath-

- eter removal in cancer patients. *Infect Control Hosp Epidemiol* 1995; 16: 451–8.
114. Popovich KJ, Hota B, Hayes R, Weinstein RA, Hayden MK. Effectiveness of routine patient cleansing with chlorhexidine gluconate for infection prevention in the medical intensive care unit. *Infect Control Hosp Epidemiol* 2009; 30: 959–63.
 115. Bleasdale SC, Trick WE, Gonzalez IM, Lyles RD, Hayden MK, Weinstein RA. Effectiveness of chlorhexidine bathing to reduce catheter-associated bloodstream infections in medical intensive care unit patients. *Arch Intern Med* 2007; 167: 2073–9.
 116. Evans HL, Dellit TH, Chan J, Nathens AB, Maier RV, Cuschieri J. Effect of chlorhexidine whole-body bathing on hospital-acquired infections among trauma patients. *Arch Surg* 2010; 145: 240–6.
 117. Climo MW, Sepkowitz KA, Zuccotti G, Fraser VJ, Warren DK, Perl TM, Speck K, Jernigan JA, Robles JR, Wong ES. The effect of daily bathing with chlorhexidine on the acquisition of methicillin-resistant *Staphylococcus aureus*, vancomycin-resistant *Enterococcus*, and healthcare-associated bloodstream infections: results of a quasi-experimental multicenter trial. *Crit Care Med* 2009; 37: 1858–65.
 118. Cook D, Randolph A, Kernerman P, Cupido C, King D, Soukup C, Brun-Buisson C. Central venous catheter replacement strategies: a systematic review of the literature. *Crit Care Med* 1997; 25: 1417–24.
 119. Vinjirayer A, Jefferson P, Ball DR. Securing central venous catheters: a comparison of sutures with staples. *Emerg Med J* 2004; 21: 582–3.
 120. Motonaga GK, Lee KK, Kirsch JR. The efficacy of the arrow staple device for securing central venous catheters to human skin. *Anesth Analg* 2004; 99: 1436–9. table of contents.
 121. Crnich CJ, Maki DG. The promise of novel technology for the prevention of intravascular device-related bloodstream infection. II. Long-term devices. *Clin Infect Dis* 2002; 34: 1362–8.
 122. Yamamoto AJ, Solomon JA, Soulen MC, Tang J, Parkinson K, Lin R, Schears GJ. Sutureless securement device reduces complications of peripherally inserted central venous catheters. *J Vasc Interv Radiol* 2002; 13: 77–81.
 123. Maki DG, Ringer M, Alvarado CJ. Prospective randomised trial of povidone-iodine, alcohol, and chlorhexidine for prevention of infection associated with central venous and arterial catheters. *Lancet* 1991; 338: 339–43.
 124. Gillies D, O’Riordan E, Carr D, O’Brien I, Frost J, Gunning R. Central venous catheter dressings: a systematic review. *J Adv Nurs* 2003; 44: 623–32.
 125. Gillies D, O’Riordan L, Carr D, Frost J, Gunning R, O’Brien I. Gauze and tape and transparent polyurethane dressings for central venous catheters. *Cochrane Database Syst Rev* 2003; CD003827.
 126. Timsit JF, Schwebel C, Bouadma L, Geffroy A, Garrouste-Orgeas M, Pease S, Herault MC, Haouache H, Calvino-Gunther S, Gustin B, Armand-Lefevre L, Leflon V, Chaplain C, Benali A, Francais A, Adrie C, Zahar JR, Thuong M, Arrault X, Croize J, Lucet JC. Chlorhexidine-impregnated sponges and less frequent dressing changes for prevention of catheter-related infections in critically ill adults: a randomized controlled trial. *JAMA* 2009; 301: 1231–41.
 127. Ho KM, Litton E. Use of chlorhexidine-impregnated dressing to prevent vascular and epidural catheter colonization and infection: a meta-analysis. *J Antimicrob Chemother* 2006; 58: 281–7.
 128. Crawford AG, Fuhr JP Jr., Rao B. Cost-benefit analysis of chlorhexidine gluconate dressing in the prevention of catheter-related bloodstream infections. *Infect Control Hosp Epidemiol* 2004; 25: 668–74.
 129. Garland JS, Alex CP, Mueller CD, Otten D, Shivpuri C, Harris MC, Naples M, Pellegrini J, Buck RK, McAuliffe TL, Goldmann DA, Maki DG. A randomized trial comparing povidone-iodine to a chlorhexidine gluconate-impregnated dressing for prevention of central venous catheter infections in neonates. *Pediatrics* 2001; 107: 1431–6.
 130. Ruschulte H, Franke M, Gastmeier P, Zenz S, Mahr KH, Buchholz S, Hertenstein B, Hecker H, Piepenbrock S. Prevention of central venous catheter related infections with chlorhexidine gluconate impregnated wound dressings: a randomized controlled trial. *Ann Hematol* 2009; 88: 267–72.
 131. Maki DG, Stolz SS, Wheeler S, Mermel LA. A prospective, randomized trial of gauze and two polyurethane dressings for site care of pulmonary artery catheters: implications for catheter management. *Crit Care Med* 1994; 22: 1729–37.
 132. Menyhay SZ, Maki DG. Preventing central venous catheter-associated bloodstream infections: development of an antiseptic barrier cap for needleless connectors. *Am J Infect Control* 2008; 36: S174.e1–5.
 133. Yebenes JC, Serra-Prat M. Clinical use of disinfectable needle-free connectors. *Am J Infect Control* 2008; 36: S175.e1–4.
 134. Casey AL, Burnell S, Whinn H, Worthington T, Faroqui MH, Elliott TS. A prospective clinical trial to evaluate the microbial barrier of a needleless connector. *J Hosp Infect* 2007; 65: 212–8.
 135. Esteve F, Pujol M, Limon E, Saballs M, Argerich MJ, Verdaguier R, Manez R, Ariza X, Gudiol F. Bloodstream infection related to catheter connections: a prospective trial of two connection systems. *J Hosp Infect* 2007; 67: 30–4.
 136. Salgado CD, Chinnes L, Paczesny TH, Cantey JR. Increased rate of catheter-related bloodstream infection associated with use of a needleless mechanical valve device at a long-term acute care hospital. *Infect Control Hosp Epidemiol* 2007; 28: 684–8.
 137. Casey AL, Worthington T, Lambert PA, Quinn D, Faroqui MH, Elliott TS. A randomized, prospective clinical trial to assess the potential infection risk associated with the PosiFlow needleless connector. *J Hosp Infect* 2003; 54: 288–93.
 138. Bouza E, Munoz P, Lopez-Rodriguez J, Jesus Perez M, Rincon C, Martin Rabadan P, Sanchez C, Bastida E. A needleless closed system device (CLAVE) protects from intravascular catheter tip and hub colonization: a prospective randomized study. *J Hosp Infect* 2003; 54: 279–87.
 139. Seymour VM, Dhallu TS, Moss HA, Tebbs SE, Elliot TS. A prospective clinical study to investigate the microbial contamination of a needleless connector. *J Hosp Infect* 2000; 45: 165–8.
 140. Raad I, Hanna HA, Awad A, Alrahwani A, Bivins C, Khan A, Richardson D, Umphrey JL, Whimbey E, Mansour G. Optimal frequency of changing intravenous administration sets: is it safe to prolong use beyond 72 hours? *Infect Control Hosp Epidemiol* 2001; 22: 136–9.
 141. de Moissac D, Jensen L. Changing i.v. administration sets: is 48 versus 24 hours safe for neutropenic patients with cancer? *Oncol Nurs Forum* 1998; 25: 907–13.
 142. Snyderman DR, Donnelly-Reidy M, Perry LK, Martin WJ. Intravenous tubing containing burettes can be safely changed at 72 hour intervals. *Infect Control* 1987; 8: 113–6.
 143. Josephson A, Gombert ME, Sierra MF, Karanfil LV, Tansino GF. The relationship between intravenous fluid contamination

- tion and the frequency of tubing replacement. *Infect Control* 1985; 6: 367–70.
144. Pellowe CM, Pratt RJ, Harper P, Loveday HP, Robinson N, Jones SR, MacRae ED, Mulhall A, Smith GW, Bray J, Carroll A, Chieveley Williams S, Colpman D, Cooper L, McInnes E, McQuarrie I, Newey JA, Peters J, Pratelli N, Richardson G, Shah PJ, Silk D, Wheatley C. Evidence-based guidelines for preventing healthcare-associated infections in primary and community care in England. *J Hosp Infect* 2003; 55 (Suppl. 2): S2–127.
 145. Randolph AG, Cook DJ, Gonzales CA, Andrew M. Benefit of heparin in central venous and pulmonary artery catheters: a meta-analysis of randomized controlled trials. *Chest* 1998; 113: 165–71.
 146. Jain G, Allon M, Saddekni S, Barker-Finkel J, Maya ID. Does heparin coating improve patency or reduce infection of tunneled dialysis catheters? *Clin J Am Soc Nephrol* 2009; 4: 1787–90.
 147. Hayashi R, Huang E, Nissenson AR. Vascular access for hemodialysis. *Nat Clin Pract Nephrol* 2006; 2: 504–13.
 148. Krzywda EA, Andris DA. Twenty-five years of advances in vascular access: bridging research to clinical practice. *Nutr Clin Pract* 2005; 20: 597–606.
 149. Schallom ME, Prentice D, Sona C, Micek ST, Skrupky LP. Heparin or 0.9% sodium chloride to maintain central venous catheter patency: a randomized trial. *Crit Care Med* 2012; 40: 1820–6.
 150. Mermel LA. Prevention of intravascular catheter-related infections. *Ann Intern Med* 2000; 132: 391–402.
 151. Ignatov A, Ignatov T, Taran A, Smith B, Costa SD, Bischoff J. Interval between port catheter flushing can be extended to four months. *Gynecol Obstet Invest* 2010; 70: 91–4.
 152. Snaterse M, Ruger W, Scholte Op Reimer WJ, Lucas C. Antibiotic-based catheter lock solutions for prevention of catheter-related bloodstream infection: a systematic review of randomised controlled trials. *Journal of Hospital Infection* 2010; 75: 1–11.
 153. Taylor RW, Palagiri AV. Central venous catheterization. *Crit Care Med* 2007; 35: 1390–6.
 154. Douard MC, Clementi E, Arlet G, Marie O, Jacob L, Schremmer B, Rouveau M, Garrouste MT, Eurin B. Negative catheter-tip culture and diagnosis of catheter-related bacteremia. *Nutrition* 1994; 10: 397–404.
 155. Maki DG, Weise CE, Sarafin HW. A semiquantitative culture method for identifying intravenous-catheter-related infection. *N Engl J Med* 1977; 296: 1305–9.
 156. Polos PG, Sahn SA. Tips for monitoring the position of a central venous catheter. How placement can go awry – even when the anatomy is normal. *J Crit Illn* 1993; 8: 660–74.
 157. Lessnau KD. Is chest radiography necessary after uncomplicated insertion of a triple-lumen catheter in the right internal jugular vein, using the anterior approach? *Chest* 2005; 127: 220–3.
 158. Pikwer A, Baath L, Perstoft I, Davidson B, Akeson J. Routine chest X-ray is not required after a low-risk central venous cannulation. *Acta Anaesthesiol Scand* 2009; 53: 1145–52.
 159. Starr DS, Cornicelli S. EKG guided placement of subclavian CVP catheters using J-wire. *Ann Surg* 1986; 204: 673–6.
 160. Bowdle A, Kharasch E, Schwid H. Pressure waveform monitoring during central venous catheterization. *Anesth Analg* 2009; 109: 2030–1, author reply 31.
 161. Bailey SH, Shapiro SB, Mone MC, Saffle JR, Morris SE, Barton RG. Is immediate chest radiograph necessary after central venous catheter placement in a surgical intensive care unit? *Am J Surg* 2000; 180: 517–21, discussion 21–2.
 162. Laronga C, Meric F, Truong MT, Mayfield C, Mansfield P. A treatment algorithm for pneumothoraces complicating central venous catheter insertion. *Am J Surg* 2000; 180: 523–6, discussion 26–7.
 163. Plaus WJ. Delayed pneumothorax after subclavian vein catheterization. *JPEN J Parenter Enteral Nutr* 1990; 14: 414–5.
 164. Plewa MC, Ledrick D, Sferra JJ. Delayed tension pneumothorax complicating central venous catheterization and positive pressure ventilation. *Am J Emerg Med* 1995; 13: 532–5.
 165. Tyburski JG, Joseph AL, Thomas GA, Saxe JM, Lucas CE. Delayed pneumothorax after central venous access: a potential hazard. *Am Surg* 1993; 59: 587–9.
 166. Cavatorta F, Campisi S, Fiorini F. Fatal pericardial tamponade by a guide wire during jugular catheter insertion. *Nephron* 1998; 79: 352.
 167. Dailey RH. Late vascular perforations by CVP catheter tips. *J Emerg Med* 1988; 6: 137–40.
 168. Jay AW, Aldridge HE. Perforation of the heart or vena cava by central venous catheters inserted for monitoring or infusion therapy. *CMAJ* 1986; 135: 1143–4.
 169. Karnachow PN. Cardiac tamponade from central venous catheterization. *CMAJ* 1986; 135: 1145–7.
 170. Duntley P, Siever J, Korwes ML, Harpel K, Heffner JE. Vascular erosion by central venous catheters. Clinical features and outcome. *Chest* 1992; 101: 1633–8.
 171. Pawlik MT, Kutz N, Keyl C, Lemberger P, Hansen E. Central venous catheter placement: comparison of the intravascular guidewire and the fluid column electrocardiograms. *Eur J Anaesthesiol* 2004; 21: 594–9.
 172. Stuart RK, Shikora SA, Akerman P, Lowell JA, Baxter JK, Apovian C, Champagne C, Jennings A, Keane-Ellison M, Bistrrian BR. Incidence of arrhythmia with central venous catheter insertion and exchange. *JPEN J Parenter Enteral Nutr* 1990; 14: 152–5.
 173. Unnikrishnan D, Idris N, Varshneya N. Complete heart block during central venous catheter placement in a patient with pre-existing left bundle branch block. *Br J Anaesth* 2003; 91: 747–9.
 174. Quiney NF. Sudden death after central venous cannulation. *Can J Anaesth* 1994; 41: 513–5.
 175. Doehring MC. An unexpected complication of central line placement. *Acad Emerg Med* 2001; 8: 854.
 176. Reuber M, Dunkley LA, Turton EP, Bell MD, Bamford JM. Stroke after internal jugular venous cannulation. *Acta Neurol Scand* 2002; 105: 235–9.
 177. Kusminsky RE. Complications of central venous catheterization. *J Am Coll Surg* 2007; 204: 681–96.
 178. Jahromi BS, Tummala RP, Levy EI. Inadvertent subclavian artery catheter placement complicated by stroke: endovascular management and review. *Catheter Cardiovasc Interv* 2009; 73: 706–11.
 179. Becker GJ, Benenati JF, Zemel G, Sallee DS, Suarez CA, Roeren TK, Katzen BT. Percutaneous placement of a balloon-expandable intraluminal graft for life-threatening subclavian arterial hemorrhage. *J Vasc Interv Radiol* 1991; 2: 225–9.
 180. Guilbert MC, Elkouri S, Bracco D, Corriveau MM, Beaudoin N, Dubois MJ, Bruneau L, Blair JF. Arterial trauma during central venous catheter insertion: Case series, review and proposed algorithm. *J Vasc Surg* 2008; 48: 918–25, discussion 25.
 181. Guimaraes M, Uflacker R, Schonholz C, Hannegan C, Selby B. Use of percutaneous closure devices in the removal of central venous catheters from inadvertent arterial catheterizations. *J Cardiovasc Surg (Torino)* 2008; 49: 345–50.

182. Jeganathan R, Harkin DW, Lowry P, Lee B. Iatrogenic subclavian artery pseudoaneurysm causing airway compromise: treatment with percutaneous thrombin injection. *J Vasc Surg* 2004; 40: 371–4.
183. Nicholson T, Ettles D, Robinson G. Managing inadvertent arterial catheterization during central venous access procedures. *Cardiovasc Intervent Radiol* 2004; 27: 21–5.
184. Wolfe TJ, Smith TP, Alexander MJ, Zaidat OO. Endovascular treatment of inadvertent cannulation of the vertebro-subclavian arterial junction. *Neurocrit Care* 2007; 6: 113–6.
185. Defalque RJ, Fletcher MV. Neurological complications of central venous cannulation. *JPEN J Parenter Enteral Nutr* 1988; 12: 406–9.
186. Vesely TM. Air embolism during insertion of central venous catheters. *J Vasc Interv Radiol* 2001; 12: 1291–5.
187. Eisenhauer ED, Derveloy RJ, Hastings PR. Prospective evaluation of central venous pressure (CVP) catheters in a large city-county hospital. *Ann Surg* 1982; 196: 560–4.
188. Heckmann JG, Lang CJ, Kindler K, Huk W, Erbguth FJ, Neundorfer B. Neurologic manifestations of cerebral air embolism as a complication of central venous catheterization. *Crit Care Med* 2000; 28: 1621–5.
189. Klein HO, Segni ED, Kaplinsky E. Unsuspected cerebral perfusion. A complication of the use of a central venous pressure catheter. *Chest* 1978; 74: 109–10.
190. Fabri PJ, Mirtallo JM, Ebbert ML, Kudsk KA, Powell C, Ruberg RL. Clinical effect of nonthrombotic total parenteral nutrition catheters. *JPEN J Parenter Enteral Nutr* 1984; 8: 705–7.
191. Fabri PJ, Mirtallo JM, Ruberg RL, Kudsk KA, Denning DA, Ellison EC, Schaffer P. Incidence and prevention of thrombosis of the subclavian vein during total parenteral nutrition. *Surg Gynecol Obstet* 1982; 155: 238–40.
192. Ruggiero RP, Aisenstein TJ. Central catheter fibrin sleeve – heparin effect. *JPEN J Parenter Enteral Nutr* 1983; 7: 270–3.
193. Macoviak JA, Melnik G, McLean G, Lunderquist A, Singer R, Forlaw L, Rombeau JL. The effect of low-dose heparin on the prevention of venous thrombosis in patients receiving short-term parenteral nutrition. *Curr Surg* 1984; 41: 98–100.
194. Dentali F, Gianni M, Agnelli G, Ageno W. Association between inherited thrombophilic abnormalities and central venous catheter thrombosis in patients with cancer: a meta-analysis. *J Thromb Haemost* 2008; 6: 70–5.
195. Burihan E, de Figueiredo LF, Francisco Junior J, Miranda Junior F. Upper-extremity deep venous thrombosis: analysis of 52 cases. *Cardiovasc Surg* 1993; 1: 19–22.
196. Lindblad B, Tengborn L, Bergqvist D. Deep vein thrombosis of the axillary-subclavian veins: epidemiologic data, effects of different types of treatment and late sequelae. *Eur J Vasc Surg* 1988; 2: 161–5.
197. Marinella MA, Kathula SK, Markert RJ. Spectrum of upper-extremity deep venous thrombosis in a community teaching hospital. *Heart Lung* 2000; 29: 113–7.
198. Buller HR, Agnelli G, Hull RD, Hyers TM, Prins MH, Raskob GE. Antithrombotic therapy for venous thromboembolic disease: the Seventh ACCP Conference on Antithrombotic and Thrombolytic Therapy. *Chest* 2004; 126: 401S–28S.
199. Baskin JL, Pui CH, Reiss U, Wilimas JA, Metzger ML, Ribeiro RC, Howard SC. Management of occlusion and thrombosis associated with long-term indwelling central venous catheters. *Lancet* 2009; 374: 159–69.
200. Rooden CJ, Tesselaar ME, Osanto S, Rosendaal FR, Huisman MV. Deep vein thrombosis associated with central venous catheters – a review. *J Thromb Haemost* 2005; 3: 2409–19.
201. Kearon C, Kahn SR, Agnelli G, Goldhaber S, Raskob GE, Comerota AJ. Antithrombotic therapy for venous thromboembolic disease: American College of Chest Physicians Evidence-Based Clinical Practice Guidelines (8th Edition). *Chest* 2008; 133: 454S–545S.
202. Ponc D, Irwin D, Haire WD, Hill PA, Li X, McCluskey ER. Recombinant tissue plasminogen activator (alteplase) for restoration of flow in occluded central venous access devices: a double-blind placebo-controlled trial – the Cardiovascular Thrombolytic to Open Occluded Lines (COOL) efficacy trial. *J Vasc Interv Radiol* 2001; 12: 951–5.
203. Crain MR, Mewissen MW, Ostrowski GJ, Paz-Fumagalli R, Beres RA, Wertz RA. Fibrin sleeve stripping for salvage of failing hemodialysis catheters: technique and initial results. *Radiology* 1996; 198: 41–4.
204. Hoshal VL Jr., Ause RG, Hoskins PA. Fibrin sleeve formation on indwelling subclavian central venous catheters. *Arch Surg* 1971; 102: 353–8.
205. Balestreri L, De Cicco M, Matovic M, Coran F, Morassut S. Central venous catheter-related thrombosis in clinically asymptomatic oncologic patients: a phlebographic study. *Eur J Radiol* 1995; 20: 108–11.
206. Frizzelli R, Tortelli O, Di Comite V, Ghirardi R, Pinzi C, Scarduelli C. Deep venous thrombosis of the neck and pulmonary embolism in patients with a central venous catheter admitted to cardiac rehabilitation after cardiac surgery: a prospective study of 815 patients. *Intern Emerg Med* 2008; 3: 325–30.
207. Paauw JD, Borders H, Ingalls N, Boomstra S, Lambke S, Fedeson B, Goldsmith A, Davis AT. The incidence of PICC line-associated thrombosis with and without the use of prophylactic anticoagulants. *JPEN J Parenter Enteral Nutr* 2008; 32: 443–7.
208. Lobo BL, Vaidean G, Broyles J, Reaves AB, Shorr RI. Risk of venous thromboembolism in hospitalized patients with peripherally inserted central catheters. *J Hosp Med* 2009; 4: 417–22.
209. Isma N, Svensson PJ, Gottsater A, Lindblad B. Upper extremity deep venous thrombosis in the population-based Malmo Thrombophilia Study (MATS). *Epidemiology, risk factors, recurrence risk, and mortality. Thromb Res* 2010; 125: e335–8.
210. McHugh GJ, Wild DJ, Havill JH. Polyurethane central venous catheters, hydrochloric acid and 70% ethanol: a safety evaluation. *Anaesth Intensive Care* 1997; 25: 350–3.
211. Kerner JA Jr., Garcia-Careaga MG, Fisher AA, Poole RL. Treatment of catheter occlusion in pediatric patients. *JPEN J Parenter Enteral Nutr* 2006; 30: S73–81.
212. Shulman RJ, Reed T, Pitre D, Laine L. Use of hydrochloric acid to clear obstructed central venous catheters. *JPEN J Parenter Enteral Nutr* 1988; 12: 509–10.
213. Agarwal AK. Central vein stenosis: current concepts. *Adv Chronic Kidney Dis* 2009; 16: 360–70.
214. Pikwer A, Acosta S, Kolbel T, Akesson J. Endovascular intervention for central venous cannulation in patients with vascular occlusion after previous catheterization. *J Vasc Access* 2010; 11: 323–8.
215. Allen AW, Megargell JL, Brown DB, Lynch FC, Singh H, Singh Y, Waybill PN. Venous thrombosis associated with the placement of peripherally inserted central catheters. *J Vasc Interv Radiol* 2000; 11: 1309–14.
216. Weiss MF, Scivittaro V, Anderson JM. Oxidative stress and increased expression of growth factors in lesions of failed hemodialysis access. *Am J Kidney Dis* 2001; 37: 970–80.
217. Palabrica T, Lobb R, Furie BC, Aronovitz M, Benjamin C, Hsu YM, Sajer SA, Furie B. Leukocyte accumulation pro-

- moting fibrin deposition is mediated in vivo by P-selectin on adherent platelets. *Nature* 1992; 359: 848–51.
218. Forauer AR, Theoharis C. Histologic changes in the human vein wall adjacent to indwelling central venous catheters. *J Vasc Interv Radiol* 2003; 14: 1163–8.
 219. Dede D, Akmangit I, Yildirim ZN, Sanverdi E, Sayin B. Ultrasonography and fluoroscopy-guided insertion of chest ports. *Eur J Surg Oncol* 2008; 34: 1340–3.
 220. Barsuk JH, McGaghie WC, Cohen ER, O'Leary KJ, Wayne DB. Simulation-based mastery learning reduces complications during central venous catheter insertion in a medical intensive care unit. *Crit Care Med* 2009; 37: 2697–701.
 221. Barsuk JH, Ahya SN, Cohen ER, McGaghie WC, Wayne DB. Mastery learning of temporary hemodialysis catheter insertion by nephrology fellows using simulation technology and deliberate practice. *Am J Kidney Dis* 2009; 54: 70–6.
 222. Britt RC, Novosel TJ, Britt LD, Sullivan M. The impact of central line simulation before the ICU experience. *Am J Surg* 2009; 197: 533–6.
 223. Barsuk JH, McGaghie WC, Cohen ER, Balachandran JS, Wayne DB. Use of simulation-based mastery learning to improve the quality of central venous catheter placement in a medical intensive care unit. *J Hosp Med* 2009; 4: 397–403.
 224. Lee AC, Thompson C, Frank J, Beecker J, Yeung M, Woo MY, Cardinal P. Effectiveness of a novel training program for emergency medicine residents in ultrasound-guided insertion of central venous catheters. *CJEM* 2009; 11: 343–8.
 225. Andreatta P, Chen Y, Marsh M, Cho K. Simulation-based training improves applied clinical placement of ultrasound-guided PICCs. *Support Care Cancer* 2010; 19: 539–43.
 226. Smith CC, Huang GC, Newman LR, Clardy PF, Feller-Kopman D, Cho M, Ennacheril T, Schwartzstein RM. Simulation training and its effect on long-term resident performance in central venous catheterization. *Simul Healthc* 2010; 5: 146–51.
 227. Evans LV, Dodge KL, Shah TD, Kaplan LJ, Siegel MD, Moore CL, Hamann CJ, Lin Z, D'Onofrio G. Simulation training in central venous catheter insertion: improved performance in clinical practice. *Acad Med* 2010; 85: 1462–9.
 228. Barsuk JH, Cohen ER, McGaghie WC, Wayne DB. Long-term retention of central venous catheter insertion skills after simulation-based mastery learning. *Acad Med* 2010; 85: S9–12.
 229. Guzzo JL, Seagull FJ, Bochicchio GV, Sisley A, Mackenzie CF, Dutton RP, Scalea T, Xiao Y. Mentors decrease compliance with best sterile practices during central venous catheter placement in the trauma resuscitation unit. *Surg Infect (Larchmt)* 2006; 7: 15–20.
 230. Rubinson L, Wu AW, Haponik EE, Diette GB. Why is it that internists do not follow guidelines for preventing intravascular catheter infections? *Infect Control Hosp Epidemiol* 2005; 26: 525–33.
 231. Runcie CJ. Assessing the performance of a consultant anaesthetist by control chart methodology. *Anaesthesia* 2009; 64: 293–6.

Address:
 Dr Peter Frykholm
 Department of Surgical Sciences
 Uppsala University
 Anaesthesiology and Intensive Care Medicine
 SE-751 85 Uppsala
 Sweden
 e-mail: peter.frykholm@akademiska.se

Appendix 1. Literature retrieval strategies for the major topics addressed in the Swedish guidelines on clinical management of central venous catheters. For each retrieval process, we report the total number of papers initially obtained, the number of papers subjected to screening based on the title and/or abstract, and the number of papers read and evaluated by the authors

Bleeding diathesis

Search pattern: ('Catheterization, Central Venous') AND ('Blood Coagulation Tests'[Mesh]) OR (blood coagulation disorders) OR ('Anticoagulants'[Pharmacological Action]) OR ('Fibrinolytic Agents'[Pharmacological Action]) OR ('Platelet Aggregation Inhibitors'[Pharmacological Action]) OR ('bleeding time').

Hits: 900; screened: 50; evaluated: 23.

Vascular access site

Search pattern: ('Catheterization, Central Venous/adverse effects')[Mesh] AND (('Jugular Veins')[Mesh] OR ('Subclavian Vein')[Mesh] OR ('Femoral Vein'))[Mesh] AND (('Venous Thrombosis')[Mesh] OR ('Upper Extremity Deep Vein Thrombosis')[Mesh] OR ('Catheter-Related Infections')[Mesh] OR ('Pneumothorax')[Mesh] OR ('Hemothorax')[Mesh])

Hits: 202; screened: 79; evaluated: 29. Additional studies from reference lists: 15.

Catheter tip positioning

Search pattern: ('Catheterization, Central Venous/adverse effects')[Mesh] AND (('Renal Dialysis')[Mesh] OR ('Vascular System Injuries')[Mesh] OR ('Central Venous Pressure')[Mesh] OR ('Extravasation of Diagnostic and Therapeutic Materials')[Mesh] OR ('Radiography')[Mesh])

Hits: 1358; screened: 200; evaluated: 44.

Infection

Search pattern: (('central venous catheters'[MeSH Terms] OR ('central'[All Fields] AND 'venous'[All Fields] AND 'catheters'[All Fields]) OR 'central venous catheters'[All Fields] OR ('central'[All Fields] AND 'venous'[All Fields] AND 'catheter'[All Fields]) OR 'central venous catheter'[All Fields]) AND ('infection'[MeSH Terms] OR 'infection'[All Fields] OR 'communicable diseases'[MeSH Terms] OR ('communicable'

[All Fields] AND 'diseases'[All Fields]) OR 'communicable diseases'[All Fields])) AND (('0001/01/01'[PDAT] : '1999/12/31'[PDAT]) AND English[lang])

Hits: >4000, evaluated: 148.

Associated mechanical complications

Search pattern: ('Catheterization, Central Venous')[Mesh] AND (('Extravasation of Diagnostic and Therapeutic Materials')[Mesh] OR ('Postoperative Complications')[Mesh] OR ('Pneumothorax')[Mesh] OR ('Hemothorax')[Mesh] OR ('Arrhythmias, Cardiac')[Mesh] OR ('Hematoma')[Mesh] OR ('Arteries')[Mesh] OR ('Peripheral Nerve Injuries')[Mesh] OR ('Embolism, Air')[Mesh])

Hits: 1849; screened: 248; evaluated: 35.

Thromboembolism

Search pattern: ('Catheterization, Central Venous')[Mesh] AND ('Occlusion') OR ('Thrombosis')[Mesh] OR ('Constriction, Pathologic')[Mesh] OR ('Stenosis') OR ('Pulmonary Embolism')[Mesh] OR ('Thrombolytic Therapy')[Mesh] OR ('Radiography')[Mesh] OR ('Magnetic Resonance Imaging')[Mesh])

Hits: 2883; screened: 400; evaluated: 29.

Training and follow-up

Search pattern: (('Learning') OR ('Teaching') OR ('Education')) AND ('Catheterization, Central Venous')

Hits: 787; screened: 29; evaluated: 29.

Appendix 2. Levels of evidence and grades of recommendation according to the Oxford Centre for Evidence-Based Medicine (revised in March 2009)

Level of evidence

- | | |
|------------|---|
| 1 a | Systematic analysis (with homogeneity) of randomised controlled studies |
| 1 b | Individual randomised controlled study (with narrow confidence interval) |
| 1 c | All-or-none-criterion (applicable when all (or some) patients died before the studied treatment was available and some (or all) survive with the studied treatment) |
| 2 a | Systematic analysis (with homogeneity) of cohort studies |
| 2 b | Individual cohort study (including randomised controlled studies with low quality) |
| 2 c | 'Outcomes' research |
| 3 a | Systematic analysis (with homogeneity) of case-control studies |
| 3 b | Individual case-control study |
| 4 | Case-series (and poor quality cohort and case-control studies) |
| 5 | Expert opinion without explicit critical appraisal, or based on physiology, bench research or 'first principles' |
-

Grade of recommendation

- | | |
|----------|---|
| A | Consistent level 1 studies |
| B | Consistent level 2 or 3 studies OR extrapolations from level 1 studies |
| C | Level 4 studies OR extrapolations from level 2 or 3 studies |
| D | Level 5, expert opinion evidence OR troublingly inconsistent or inconclusive studies of any level |
-